

Diagnostic Radiology Routine Manual

Gundersen Health System

HEAD/NECK	HEADWORK ROUTINES	5
	SKULL POSITIONING LINES	6
	VP SHUNT CHECK	7
	SHUNT CHECK	9
	SHUNT SERIES - MULTIVIEW	10
	HEADWORK POSITIONING HELP	11
	EYE FOREIGN BODY	14
	FACIAL BONES	15
	MANDIBLE	16
	SINUS	17
	NASAL BONES	18
	ORBITS	19
	SKULL	20
	SOFT TISSUE NECK	21
THORAX	AGE SPECIFIC CHEST XRAYs	22
	CHEST-ADULT	23
	CHEST-CHILD	24
	CHEST B-READ	25
	CHEST-PORTABLE	26
	CHEST-CHILD PORTABLE	27
	CHEST-DECUBITUS	28
	CHEST FOR LEADLESS PACEMAKER	29
	CHEST FOR LEADLESS PACEMAKER	29
	CHEST-APICAL LORDOTIC	30
	RIBS	31
	STERNUM	32
	STERNOCLAVICULAR (SC) JOINTS	33
ABDOMEN	ABDOMEN WITH CONTRAST	34
	ABDOMEN/KUB	35
	SMALL BOWEL SERIES - GASTROVIEW ADHESIVE OBSTRUCTION	36
	BABYGRAM	38
	BABYGRAM STILLBORN	39
	NOSE TO RECTUM FOR FOREIGN BODY	40

SPINE

CERVICAL SPINE	41
CERVICAL SPINE-FLEXION/EXTENSION	42
CERVICAL SPINE-OBLIQUES	43
CERVICAL THORACIC SPINE	44
THORACIC (DORSAL) SPINE	45
THORACOLUMBAR SPINE	46
LUMBOSACRAL SPINE	47
LUMBOSACRAL SPINE F/U ARTHROPLASTY	48
SCOLIOSIS	49
SCOLIOSIS – BEND VIEWS	50
ENTIRE SPINE-PRE ECT WORK UP	51

UPPER EXTREMITY

CLAVICLE	52
ACROMIO-CLAVICULAR JOINTS	53
INFANT UPPER EXTREMITY	54
SHOULDER	55
GARTH METHOD (AP APICAL OBLIQUE AXIAL) SHOULDER	56
STRYKER “NOTCH” METHOD (AP AXIAL PROJECTION)	57
VELPEAU AXILLARY SHOULDER	58
WEST POINT AXILLARY SHOULDER	59
ZANCA (SHOULDER/ AC JOINTS)	60
BICIPITAL GROOVE (TANGENTIAL-INTERTUBERCULAR) SHOULDER	61
SCAPULA	62
HUMERUS	63
ELBOW	64
ELBOW-STRESS VIEW	65
FOREARM	66
WRIST	67
WRIST-CARPAL TUNNEL	68
WRIST-NAVICULAR VIEWS	69
WRIST-FIST OR GRIPPING VIEWS	70
HAND	71
HAND-Bone Age	72
FINGER	73
THUMB	74
THUMB-ROBERTS VIEW	75

LOWER EXTREMITY

THUMB-STRESS VIEW	76
INFANT LOWER EXTREMITY	77
HIP TO ANKLE/LEG LENGTH	78
FALSE PROFILE HIP TO ANKLE	79
SCANOGRAM	80
SACRUM/COCCYX	81
SACROILIAC JOINTS	82
PELVIS	83
PELVIS-INLET/OUTLET VIEWS	84
PELVIS-JUDET VIEWS	85
HIP	86
FALSE PROFILE HIP	87
DUNN HIP/PELVIS	88
PELVIS INSTABILITY SERIES	89
2 VIEW PELVIS (WITH AND WITHOUT CORI) (DR. LEHMAN AND DR. WHALEN)	90
FEMUR	91
KNEE	92
KNEE-TUNNEL (CAMP COVENTRY)	93
KNEE-TUNNEL (HOLMBLAD)	94
AP STRESS KNEE	95
TELOS KNEE	96
TIBIA/FIBULA	97
ANKLE	98
ANKLE - SPECIALTY VIEWS (inversion stress, anterior drawer, and long leg axial views)	99
ANKLE- SPECIALTY VIEWS (gravity stress and canale views)	100
PODIATRIC SPECIALTY VIEWS (hindfoot alignment, charger, sunrise, brodens, and harris/beath)	101
OS CALCIS (HEEL)	102
FOOT	103
FOOT-CLUB FOOT	104
TOES	105
FOOT-SESAMOIDS	106
PEDIATRIC TRAUMA SURVEY	107
BONE SURVEY COMPLETE	108
GENETIC BONE SURVEY	109
LONG BONE SURVEY	110

SURVEYS

PROVIDER SURVEYS

SIALOGRAM	111
XR POSSIBLE RETAINED SURGICAL ITEM (Missing Item in OR)	112
URETHROGRAM PROCEDURE	113
DR. JON PETERSON - PEDS ORTHO	114
DR. DUDLEY PROTOCOLS	115

HEADWORK ROUTINES

[Click here for "Headwork Positioning Help"](#)

FACIAL BONES: PA Waters, Caldwell, Lateral & Modified Waters.

MANDIBLE: Towne, PA, Bilateral Obliques (best visualized on Panorex, if possible).

MASTOIDS: Towne, Schullers & Chasse III.

MAXILLAE: Facial Bones Routine.

NASAL BONES: Waters & Both Laterals.

OPTIC FORAMINA: Bilateral Rhese.

ORBITS: Waters, True Caldwell & Lateral of affected side.

PETROUS RIDGES: Stenvers & AP Towne.

SELLA TURCIA: Lateral Skull.

SINUS: PA Waters, Caldwell & Lateral.

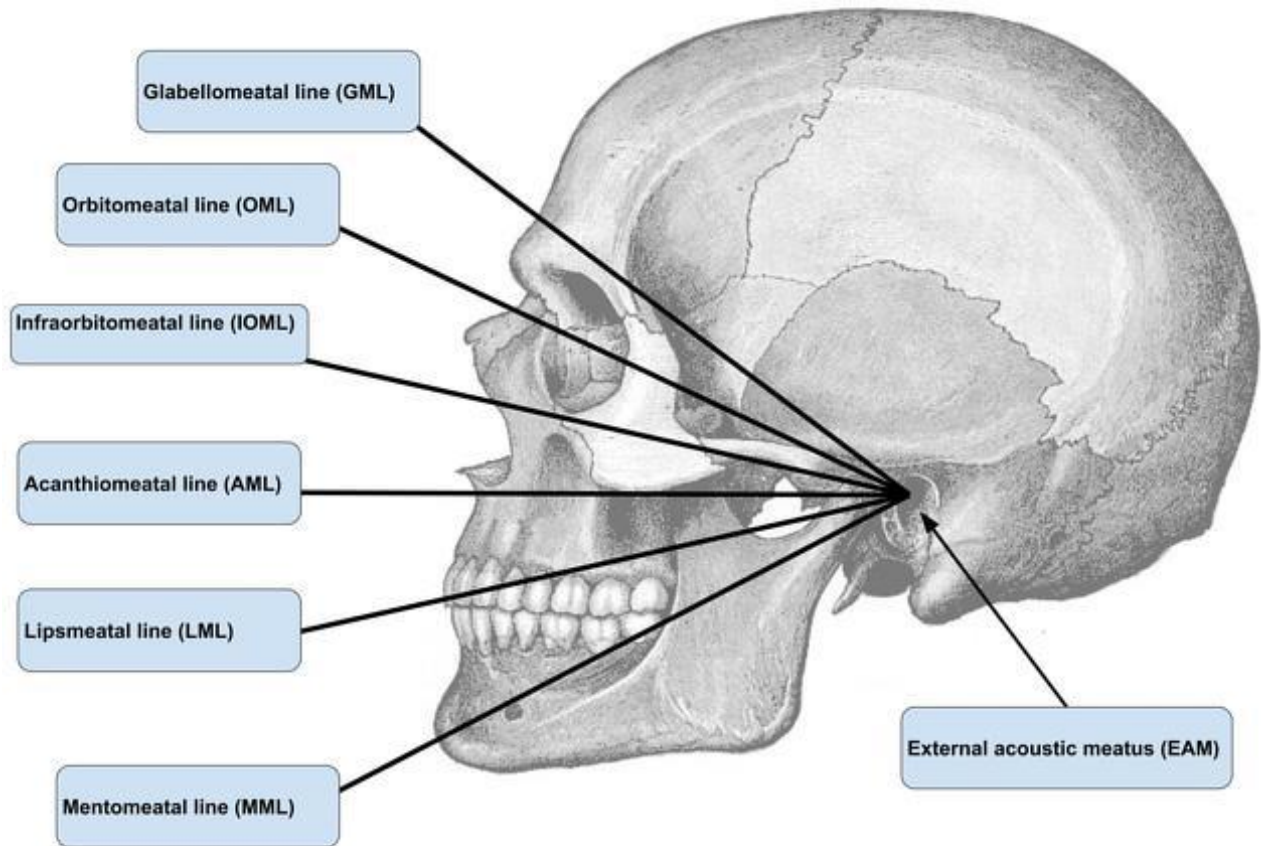
SKULL: PA, AP Towne, Left Lateral & SMV.

For trauma/injury: AP, AP Towne and both Laterals done X-table.

TEMPOROMANDIBULAR JOINTS (TMJ's): Open mouth Towne, Open & Closed Mouth Laterals

ZYGOMATIC ARCHES: Water's, Towne, SMV (Basal) & Oblique Axial
Bilaterally, Modified Towne

SKULL POSITIONING LINES



XR SHUNT – VP CHECK

VP SHUNT CHECK

ROUTINE: Single view of the skull to view valve pressure setting.

DISTANCE: 40”

BUCKY: YES

FOCAL SPOT: Large

IMAGING PLATE: DR-16x16 Detector

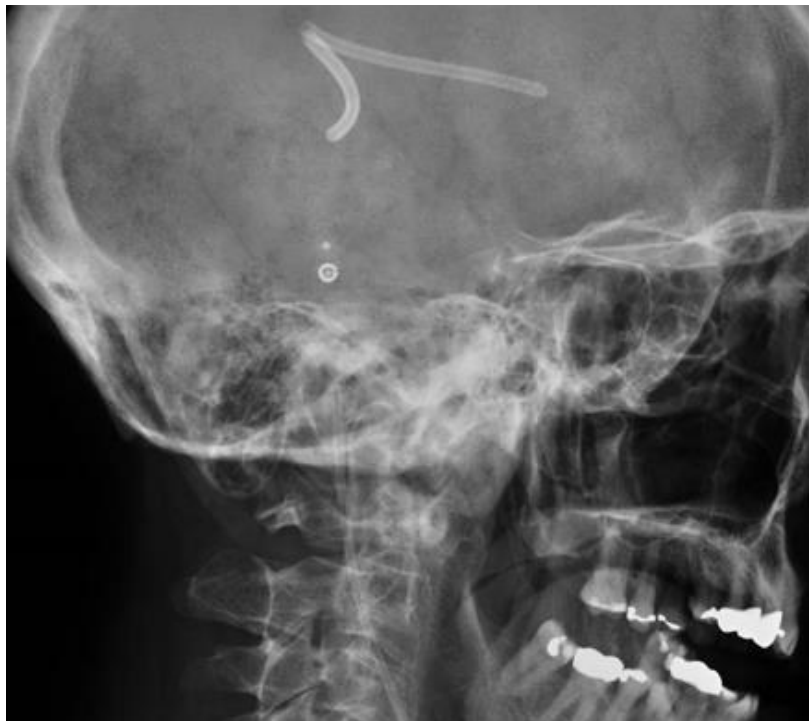CENTRAL RAY: Perpendicular to the image receptor centered on appropriate part.

ADDITIONAL COMMENTS:

- This pressure check is usually done under fluoroscopy in the Pain Clinic but can also be verified with an x-ray of the valve.
- Position to see valve – entire skull does not need to be included.

HELPFUL POSITIONING:

See following page.



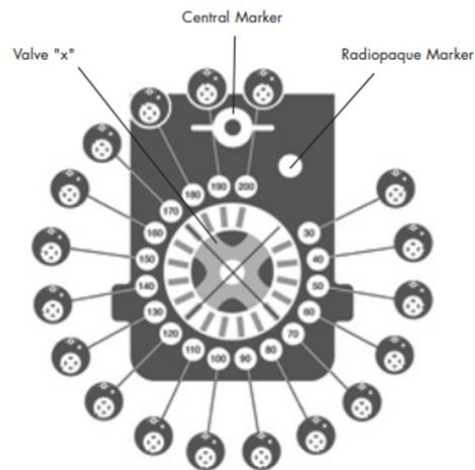
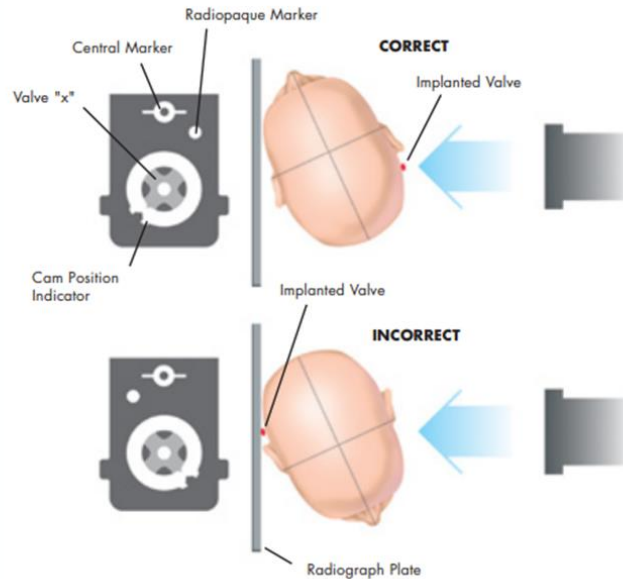
PRESSURE SETTING VERIFICATION

It is advisable to x-ray the complete system immediately after implantation to have a permanent record of component placement and to verify valve pressure. It is also advisable to x-ray the valve whenever valve pressure is reprogrammed or if the patient undergoes an MRI.

A proper radiograph will be generated when the film is shot perpendicular to the plane of the valve with the non-implanted side of the patient's head resting on the plate. The film must be taken in relation to the valve and not the patient's anatomy.

The setting of the valve can be determined by comparing the position of the radiopaque maker on the valve cam to the fixed position of the radiopaque right-hand side indicator on the base plate of the valve.

Comparing the patient radiographs to the diagram on the programming unit panel will indicate the valve setting. Note that settings of 70, 120 and 170 mm H₂O align with the cross in the center of the valve.



Note: Remember to verify valve pressure setting after an MRI.

IMG1218 XR SHUNT 1 VIEW

SHUNT CHECK

(1 VIEW SHUNT SERIES)

ROUTINE: AP Skull
PA or AP Chest
AP Abdomen

DISTANCE: 40"

BUCKY: YES

FOCAL SPOT: Large

IMAGING PLATE: DR detector or appropriate sized CR cassette

CENTRAL RAY: Perpendicular to the image receptor centered on appropriate part.

HELPFUL POSITIONING:

SKULL- Use large enough image receptor to include a portion of the neck.

CHEST- Center high and include a portion of the neck and a portion of the abdomen on the image.

ABDOMEN- Position to see the end of the shunt. Symphysis not necessary.

ADDITIONAL COMMENTS:

1. Be sure that anatomy overlaps on the 3 images so entire shunt can be visualized.
2. **INFANTS-** Do a Lateral Skull and a Babygram.
3. If CPV views ordered see **VP Shunt Check**.

IMG1219 XR SHUNT 2 VIEWS

SHUNT SERIES - MULTIVIEW

ROUTINE: AP & Lateral Skull

PA or AP and Lateral Chest

AP and Lateral Abdomen

DISTANCE: 40"

BUCKY: YES

FOCAL SPOT: Large

IMAGING PLATE: DR-16x16 Detector or appropriate sized CR cassette

CENTRAL RAY: Perpendicular to the image receptor centered on appropriate part.

HELPFUL POSITIONING:

SKULL- Use large enough image receptor to include a portion of the neck.

CHEST- Center high and include a portion of the neck and a portion of the abdomen on the image.

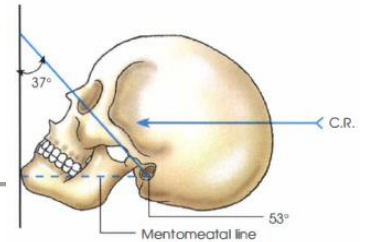
ABDOMEN- Position to see the end of the shunt. Symphysis not necessary.

ADDITIONAL COMMENTS:

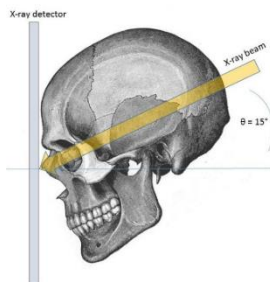
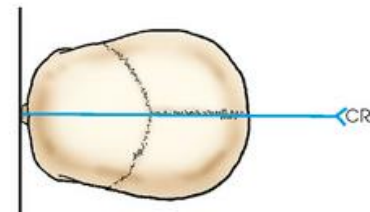
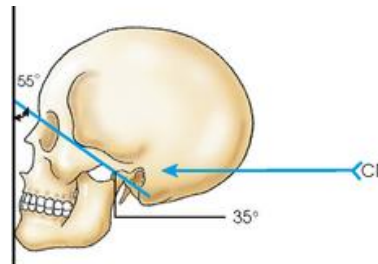
1. Be sure that anatomy overlaps on the 3 images so entire shunt can be visualized.
2. **INFANTS-**Do a Lateral Skull and a Babygram.
3. If CPV views ordered see **VP Shunt Check**.

HEADWORK POSITIONING HELP

- **PA Waters view** - the chin is raised until the mento-mandibular line (MML) is perpendicular to the receptor (OML will be 37-degrees caudal from receptor) the beam is exiting at the acanthion.

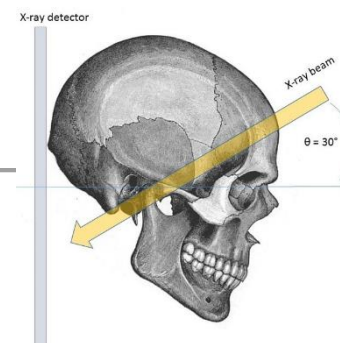


- **Modified PA Waters** - Adjust head until Lips Meatal Line (LML) is perpendicular; Orbitomeatal Line (OML) forms a 55-degree angle with the IR. Align Central Ray perpendicular, centered to exit at acanthion.

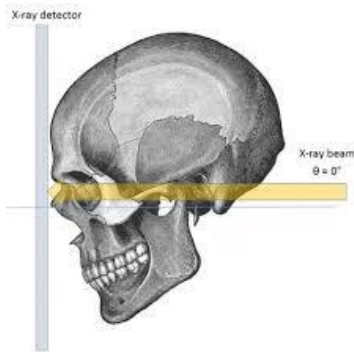


- **PA Caldwell** - the orbitomeatal line is running perpendicular to the detector. The central ray is angled caudad around 15° to exit at the nasion.

- **AP Towne** - the OML perpendicular to the image receptor. The beam travels 30-degrees caudad to the orbitomeatal line *entering at the glabella*.

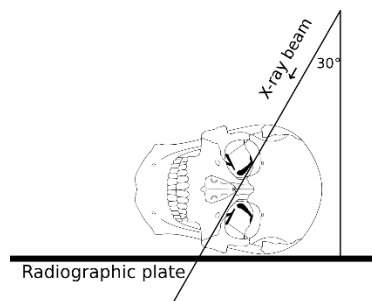
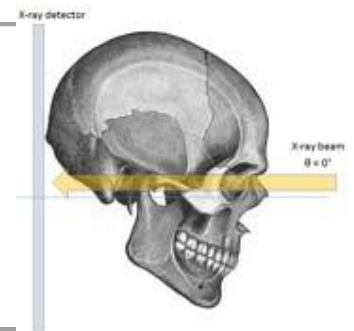


- **Modified AP Towne** - the OML perpendicular to image receptor. The beam travels 30-degrees caudad to the OML *entering 2" above the glabella*.



- **PA** the patient's forehead is placed against the image detector allowing for the nose to be in contact as well. The beam is exiting at the nasion.

- **AP** the back of patient's head is placed against the image detector. The central ray is centered at the nasion.



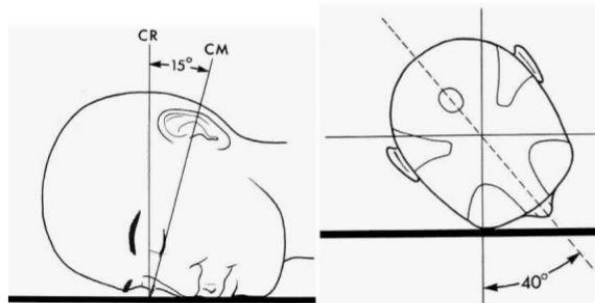
- **Schullers** Lateral projection with side of interest toward image receptor. The central beam passes from one side of the head and is at a 25° caudal angle exiting through the mastoid air cells on the side of interest.

- **Chasse III** obtained by positioning the occiput on the film, the head is rotated approximately 10-15° toward the side opposite to the one under examination and the chin flexed on the chest. There is no angulation of x-ray beam.

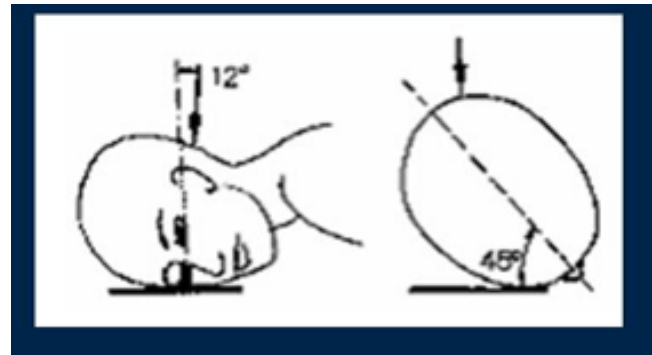
- **Open and Closed Mouth Laterals**-laterals with a 25–30-degree caudad angle, centered 5cm superior and 1 cm anterior to the EAM.

- **Rhese**

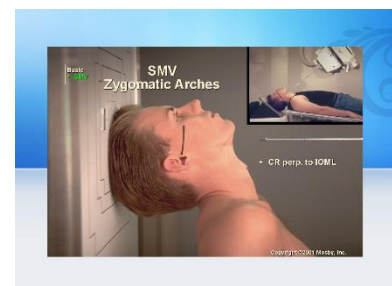
RHESE VIEW: The zygoma, nose, and chin should touch the cassette. The x-ray beam is directed posterior-anteriorly at 40 degrees to the midsagittal plane



- **Stenvers** obtained with the patient facing the film with the head slightly flexed and rotated 45° toward the side opposite to the side under examination. The x-ray beam is angulated 12-14° caudad. The long axis of the petrous pyramid becomes parallel to the plane of the film and the entire pyramid is well visualized, including its apex.



- **SMV** taken from "under the chin" has the advantage of showing both temporal bones on the same film so that comparison of both sides can be made



- **Oblique Axial** position as for an SMV then tilt head to bring mid-sagittal plane 15-degrees toward side of interest.

- **Open Mouth Town** position for a Towne and then have the patient open their mouth.

EYE FOREIGN BODY

ROUTINE: Caldwell with 30° caudal tube angulation.

DISTANCE: 40"

BUCKY: YES

FOCAL SPOT: Small

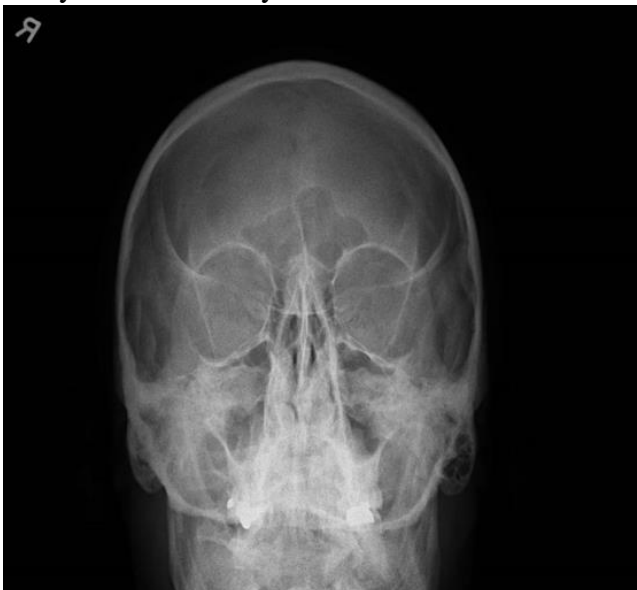IMAGING PLATE: 8x10 CR cassette or DR detector

CENTRAL RAY: 30° caudal tube angle entering at the nasion.

HELPFUL POSITIONING: PA skull normally done upright with tube angled 30° caudal to get the petrous ridges out of the orbits.

ADDITIONAL COMMENTS:

1. If technologist visualizes a foreign body, a Lateral View of the affected side must be obtained to locate the foreign body in the patient.
2. If patient has an MRI appt. that day: Send patient down to MRI. Have patient wait in waiting room. Let MRI Techs know that the patient is back from x-ray.
3. If patient is having MRI on another day: Send patient home after having exam read by Rad of the Day.



IMG1150 XR FACIAL BONES 3+ VIEWS
IMG1149 XR FACIAL BONES 1-2 VIEWS

FACIAL BONES

ROUTINE: Waters, Caldwell, Lateral, & Modified Waters.

TEC Routine: Waters, Caldwell, & Lateral of the affected side.

DISTANCE: 40"

BUCKY: YES

FOCAL SPOT: Small

IMAGING PLATE: CR-10x12 Cassettes or DR detector

CENTRAL RAY:

PA Waters: Perpendicular to the image receptor entering at the acanthion.

Caldwell: 15° caudal angle entering at the nasion.

Lateral: Perpendicular to the image receptor entering the zygoma at a level halfway between the outer canthus and the EAM.

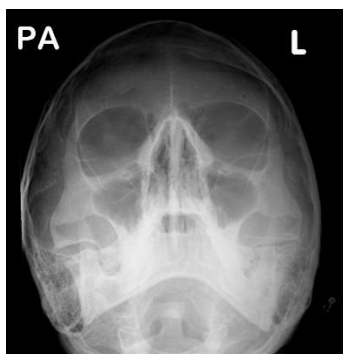
Modified Waters: Perpendicular to the image receptor entering at the acanthion.

HELPFUL POSITIONING:

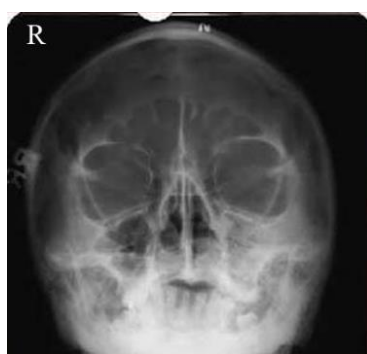Modified Water's: Pt. is PA. Nose and chin of patient resting on bucky or table. OML forms a 55° angle with the image receptor. Center image receptor to the acanthion.

ADDITIONAL COMMENTS:

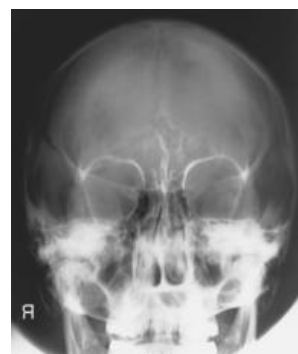1. If injury to zygomatic arches, do Oblique Axials (Tangential) of arches.
2. If unable to tip head back for Oblique Axials, do AP Axials (Modified Towne).



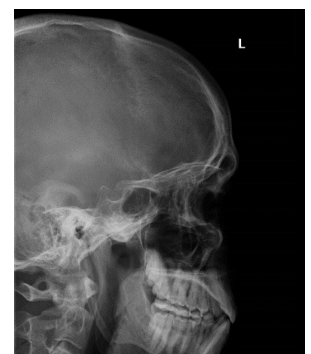
Waters



Modified Waters



Caldwell



Lateral of
affected side

IMG1110 XR MANDIBLE 4+ VIEWS
IMG1109 XR MANDIBLE 1-3 VIEWS

MANDIBLE

ROUTINE: Towne, PA, Bilateral Obliques.

DISTANCE: 40"

BUCKY: YES for PA and Towne. Obliques can be done Bucky or Non-Bucky

FOCAL SPOT: Large

IMAGING PLATE: 10x12 CR cassette or DR detector

CENTRAL RAY:

PA: Perpendicular to the image receptor entering at the junction of the lips.

Towne: 35-40° caudal angle entering at the glabella.

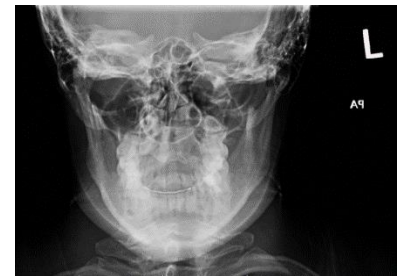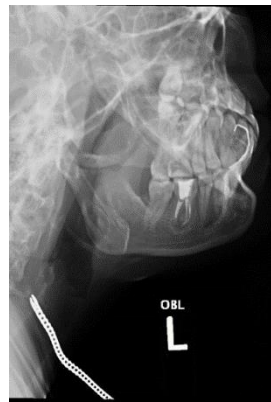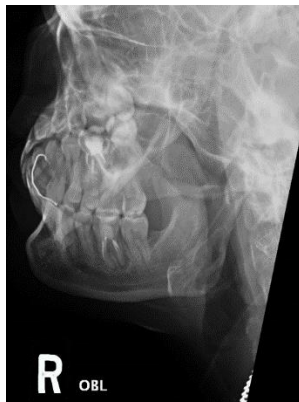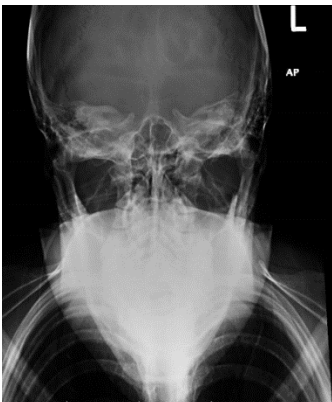
Obliques: 25° cephalic angle entering at the mandible part of interest.

HELPFUL POSITIONING:

1. *PA:* Patient's forehead and nose against the bucky. OML perpendicular to the image receptor.
2. *Towne:* Patient is AP. Tuck the chin bringing the OML perpendicular to the image receptor. Angle central ray 35-40° caudal entering at the glabella.
3. *Obliques:* Patient's head in lateral position. Oblique (tilt) head 30-45°. Angle central ray 25° cephalic to the mandible of interest (the one closest to the image receptor).

ADDITIONAL COMMENTS:

Mandible views are best obtained by doing a panorex image in the Oral Surgery department. During normal clinic hours, inform the ordering provider that a panorex equipment is available in the Oral Surgery Department on the 5th floor. If they order that instead of a mandible exam, the patient can be directed to Oral Surgery. If the patient is seen in La Crosse TEC and the Oral Surgery Resident is available, they may take the patient to Oral Surgery to do the exam. If the Oral Surgery Resident is not seeing the patient and the TEC doctor orders mandible views, the routine should be done.



Updated 12/5/2022 sla

IMG1117 XR SINUSES 1-2 VIEWS
IMG1118 XR SINUSES 3+ VIEWS

SINUS

ROUTINE: PA Waters, Caldwell, Lateral. If Provider orders a 1V Sinus, do the Waters View.

DISTANCE: 40"

BUCKY: YES

FOCAL SPOT: Large

IMAGING PLATE: 8x10 CR cassettes or DR detector

CENTRAL RAY:

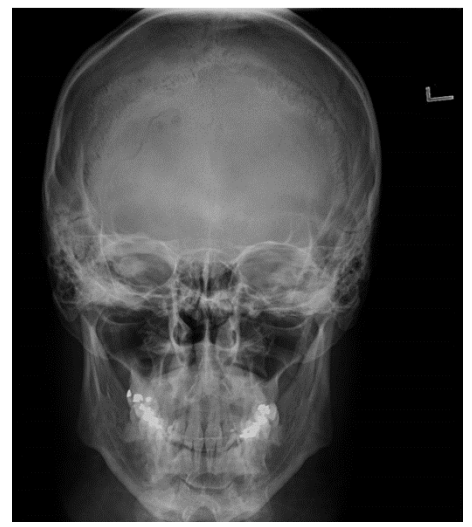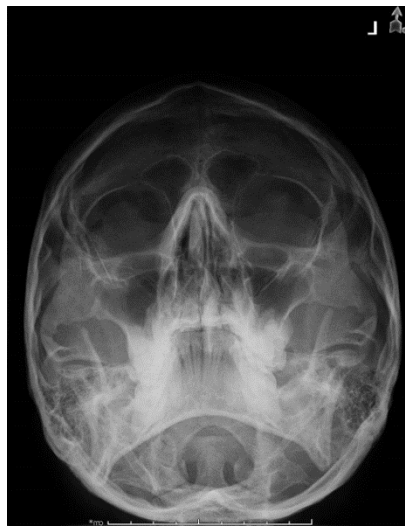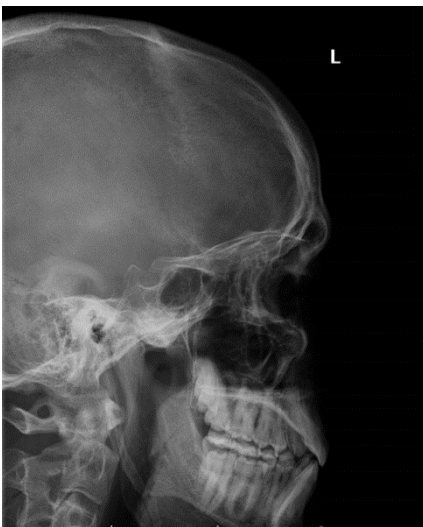
PA Waters: Perpendicular to image receptor entering at the acanthion.

Caldwell: 15° caudal angle entering at the nasion.

Lateral: Perpendicular to the image receptor entering the zygoma at a level halfway between the outer canthus and the EAM.

ADDITIONAL COMMENTS:

On Children under 3 years of age, make one attempt only at a Waters View.



IMG1111 XR NASAL BONES

NASAL BONES

ROUTINE: Waters & both Lateral views.

DISTANCE: 40"

BUCKY: YES on Waters, NO on Laterals

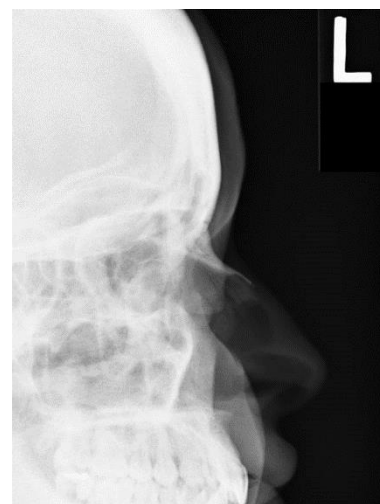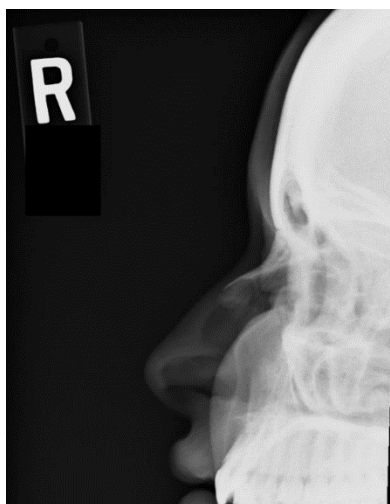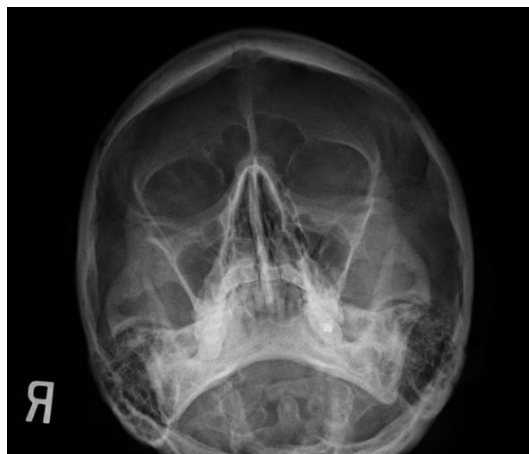
FOCAL SPOT: Small

IMAGING PLATE: 8x10 CR cassettes or DR detector

CENTRAL RAY:

Waters: Perpendicular to the image receptor entering at the acanthion.

Lateral: Perpendicular to the image receptor entering 1/2" inferior and posterior to the nasion.



ORBITS

ROUTINE: Water's, True Caldwell, and Lateral of the affected side.

DISTANCE: 40"

BUCKY: YES

FOCAL SPOT: Small

IMAGING PLATE: 8x10 CR cassette or DR detector.

CENTRAL RAY:

True Caldwell: 23° caudal tube angle exiting at the nasion with pt. PA.

Lateral: Perpendicular to the image receptor entering 2" superior to the EAM

Water's: Perpendicular to the image receptor exiting at the acanthion.

HELPFUL POSITIONING:

True Caldwell: Patient places nose and forehead against the upright bucky. Angle 23° caudally so central ray exits the nasion.

IMG 1220 XR SKULL 1 VIEW
IMG1119 XR SKULL 2-3 VIEWS
IMG1120 XR SKULL 4+ VIEWS

SKULL

ROUTINE: NO TRAUMA: PA, AP Towne, Left Lateral, & SMV.

TRAUMA: AP, AP Towne & Both Laterals (done Cross-table).

DISTANCE: 40"

BUCKY: YES

FOCAL SPOT: Large

SCREEN: 10x12 CR cassettes or DR detector

CENTRAL RAY:

PA: Perpendicular to the image receptor entering at the glabella.

AP Towne: 30° caudal angle entering 2.5 inches above the superciliary arch (about the level of the hairline).

Lateral: Perpendicular to the image receptor entering 2" superior to the EAM.

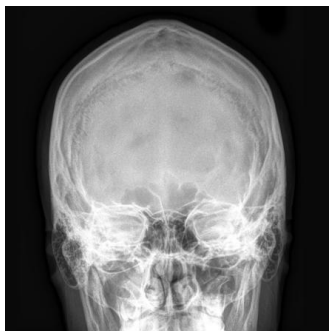SMV: Perpendicular to the image receptor entering midway between the mandibular arches and 3" inferior the point of the chin.

HELPFUL POSITIONING:

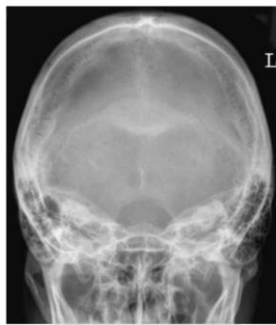AP Towne: Patient placed supine (AP) with tube angled 30° caudal. Could also do with patient prone and using a 30° cephalic angle.

ADDITIONAL COMMENTS:

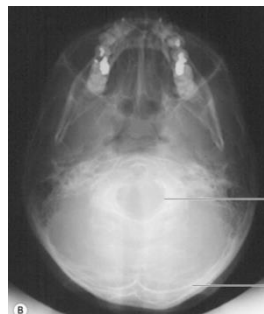1. If unable to obtain a SMV view, due to patient condition, take a Right Lateral.
2. Do NOT do a SMV view if an injury has occurred to the neck. A Right Lateral should be performed instead.
3. Always include a Left Lateral View whenever possible.



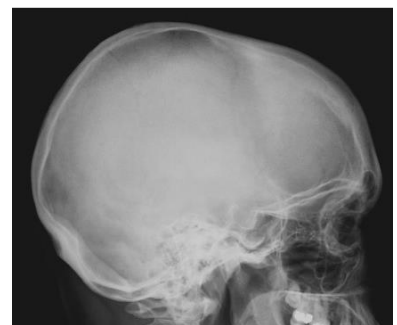PA



AP Towne



SMV



Updated 12/5/2022 sla

SOFT TISSUE NECK

ROUTINES: AP and Lateral of the neck--upright or supine. (We can only charge for a 1 view).

DISTANCE: 40"

BUCKY: Yes

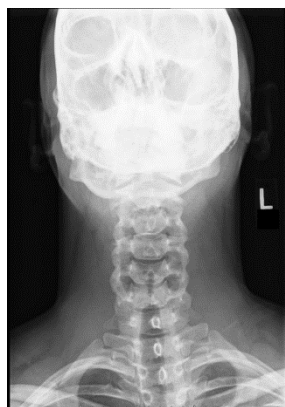
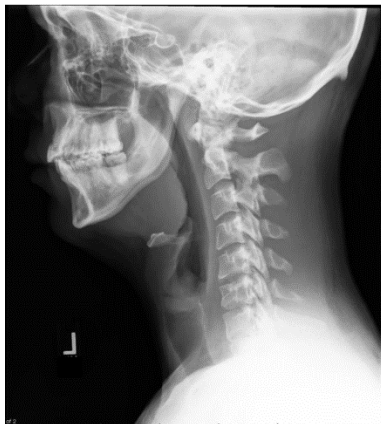FOCAL SPOT: Small

IMAGING PLATE: 10x12 CR cassette or DR detector

CENTRAL RAY: Perpendicular to the image receptor entering the neck at the level of the thyroid cartilage. *Include the entire nasal passage.*

HELPFUL POSITIONING:

1. Take exposure during slow, deep inspiration to ensure filling of upper airway with air.
2. If a child has epiglottitis, placing them in the supine position may cause obstruction so the technologist should find out whether epiglottitis is a concern.
3. **Patients suspected of epiglottitis:**
 - a. Image receptor in upright position, assuming they can sit.
 - b. Chin should be elevated, if possible.
 - c. If the ordering physician or radiologist does not see epiglottitis on the upright image, but desires a better-quality image, then a supine image can be obtained.
4. **Patients not suspected of epiglottitis:**
 - a. All infants should be done in the supine position. A bolster may be needed behind their shoulders to obtain an extended neck position. If possible, toddlers & older can be done upright. If this cannot be tolerated, a supine image may be taken.
 - b. The chin should be up.
 - c. The shoulders should be pulled down.
 - d. Patient should be mummy wrapped, sandbag on legs.



AGE SPECIFIC CHEST XRAYS

ROUTINE VIEWS: PA (preferred) or AP and Lateral

DISTANCE: Varies (see below)

BUCKY OR GRID: Age specific (see below)

IMAGING PLATE: appropriate size CR cassettes or DR detector

NEWBORN TO ONE YEAR OLD:

AP SUPINE— Done at 48” non-bucky use a “tame-em-board” if available. If not, infant should be immobilized using a head sponge & tape with their chin brought up away from their chest. Their arms should be immobilized above their head and their legs should be sandbagged or taped flat. The central ray is directed 5° caudal. The exposure should be made on full inspiration. At least 9 posterior ribs should be demonstrated on the right side. Intervertebral disc spaces should be barely visible for proper exposure.

CROSS-TABLE LATERAL— Done with the infant supine at 48” non-bucky. Infant should be immobilized as for the ap supine view either using the “tame-em-board” or lying on a large block sponge. The image receptor is placed vertically against the infant’s left side. The central ray is perpendicular to the image receptor. The exposure is made on full inspiration.

CHILD:

A child can be done either sitting or standing at 72”, non-bucky. On the PA view, have them put their hands on their hips and roll their shoulders forward to remove the scapulas from the lung field. The central ray is perpendicular to the image receptor. The exposure is made on full inspiration.

YOUNG ADULT/ADULT:

Done standing, when possible, but can be done sitting if patient cannot stand. Done at 72”. Annotate on the image whether the image was done AP or PA and if it is done anyway other than standing. If the AP is done AP Sitting on the cart, the distance is 48”. The PA is done with the patient’s hands on their hips and their shoulders rolled forward. The lateral is done with their arms over their heads & grabbing on to their elbows, if able. The central ray is perpendicular to the image receptor and done on full inspiration.

CHEST-ADULT

ROUTINE: PA (if possible, otherwise AP) & Lateral.

DISTANCE: 72"

BUCKY: YES

FOCAL SPOT: Large

IMAGING PLATE: CR-14x17 Cassette or DR detector

CENTRAL RAY:

PA/AP: Perpendicular to T-7 (7-8" below vertebral prominence).

Lateral: Perpendicular to T-7.

ADDITIONAL COMMENTS:

1. **PA Chest:** Patient puts their hands on their hips and rolls their shoulders and elbows forward to get their scapulas out of the lung fields.
2. **Lateral Chest:** Patient puts both arms over their head and grabs onto their elbows, if possible.
3. Annotate on the image whether it was done AP or PA.
4. Take image(s) on full inspiration.

SEE ALSO/OTHER VIEWS

[Go to "Decubitus Chest"](#)

[Go to "Apical Lordotic"](#)

Requests for Nipple Markers:

At the request of the Radiologists, these exams should NOT be done portably. PA and lateral views should be done in the department.

Guidelines to remember when critiquing your adult chest images:

1. If the patient is larger, use the image receptor crosswise for the PA. If the patient is tall and thin, use the image receptor lengthwise.
2. If one or both bases are clipped on the PA, repeat it. If it's close on the top, do an additional image lower for the bases and send both.
3. If both bases are clipped on the Lateral Chest, repeat it.
4. If one base is clipped on the Lateral and you have both bases on the PA, don't repeat the Lateral.
5. Use ½ inch as a guideline for rotation when looking at the Lateral—more than ½ inch, repeat it. (1/2 inch is about the width of the distal 5th finger).
6. Consider your patient's condition when reviewing the images. If you're close to the recommended guidelines and you don't think you can get a better image by repeating it, don't repeat.

IMG1131 XR CHEST 2 VIEWS (PA AND LATERAL)

CHEST-CHILD

ROUTINE: PA/AP and Lateral.

DISTANCE: 48" or 72" depending on age of child-see additional comments.

BUCKY: NO

FOCAL SPOT: Small

IMAGING PLATE: CR-8x10 or 10x12 Cassettes or DR detector

CENTRAL RAY:

PA: Perpendicular to T-7 (7-8" below vertebral prominence)

Lateral: Perpendicular to T-7.

HELPFUL POSITIONING:

1. Take upright, if possible, on children 1yr or older.
2. Utilize parents to hold patient.

ADDITIONAL COMMENTS:

Under 1 yr old: AP supine chest at 48" with a 5° caudal tube.

Lateral done cross-table at 48" with left side against image receptor.

1-3 yr old: PA sitting and *Lateral sitting* at 72" non-bucky. If child is over 1 year old and is uncooperative or cannot sit up, do supine and cross-table lateral.

IMG1287 XR CHEST B-READ

CHEST B-READ

ROUTINE: PA with nipple markers.

DISTANCE: 72"

BUCKY: Yes

FOCAL SPOT: Large

IMAGING PLATE: CR-14x17 Cassette or DR detector

CENTRAL RAY: Perpendicular to T-7 (7-8" below vertebral prominence)

ADDITIONAL COMMENTS:

1. **BBs are to be used as nipple markers on all B-Read Chests.**
2. Accurate marker usage and positioning are mandatory per national standards.
3. Contact the Office Assistants at Ext. 52213 to notify them that you've done a B-Read Chest and provide them with the patient information.

IMAGE CRITIQUE:

1. Make certain to label and mark the image properly.
2. Patient cannot be rotated.
3. Scapulae need to be out of lung fields.
4. Both costophrenic angles must be included.
5. 10 posterior ribs should be visualized.

IMG1126 XR CHEST 1 VIEW (AP OR PA)

CHEST-PORTABLE

ROUTINE: AP Chest done bedside.

DISTANCE: 48"

BUCKY: NO- *Use a Grid*

FOCAL SPOT: Large

IMAGING PLATE: CR-14x17 Cassette or DR detector

CENTRAL RAY:

AP: Perpendicular to T-7 (7-8" below vertebral prominence)

Post PICC Line placement Chest X-rays:

At the request of the Radiologists, the procedure for post PICC line placement chest x-ray is as follows: The procedure does NOT include the arm but does include the entire chest. First attempt an AP and if the line is not visible turn the patient slightly into the RPO position. Keep the KVP low to produce an image with more contrast. The image should visualize through mediastinum without burning out the lungs. These exams should be marked **STAT** and checked by a Radiologist immediately. The IV Therapy Nurse Phone # is: 50433.

Post Pectus Repair Chest X-rays

If a chest is ordered for s/p pectus repair-a *Portable AP & Cross-table Lateral Chest* may be ordered to be done in PAR after surgery. Don't roll, log roll, or twist the patient when placing the cassette.

Requests for Nipple Markers:

At the request of the Radiologists, these exams should NOT be done portably. PA and lateral views should be done in the department.

IMG1126 XR CHEST 1 VIEW (AP OR PA)

CHEST-CHILD PORTABLE

ROUTINE: AP Supine Chest done bedside. Cross-table Lateral done if ordered.

DISTANCE: 48"

BUCKY: NO

FOCAL SPOT: Large

IMAGING PLATE: 8x10 or 10x12 CR Cassette or DR detector

CENTRAL RAY:

AP: Perpendicular to image receptor

ALWAYS WASH YOUR HANDS WHEN ENTERING THE NICU/PICU/NURSERY.

**ALWAYS MAKE SURE THAT THE XRAY IS MARKED AND ANNOTATED
CORRECTLY.**

Baby in an open Isolette:

Put cassette in the tray that slides out from under the isolette, use the numbers and letters on the tray to line up the cassette. The nurse should place the shield & marker.

Baby in a closed Isolette:

Put cassette in a cloth diaper and place directly under the patient. You may have to move the baby away from the part of the isolette that is curved over them- Don't have the central ray going through that curved portion of the isolette.

IMG1130 XR CHEST 1 VIEW (SPECIFY SPECIAL VIEW)

CHEST-DECUBITUS

ROUTINE: Place patient on cart requested side down. (Does not matter if done PA or AP).

DISTANCE: 72"

BUCKY: Yes

FOCAL SPOT: Large

IMAGING PLATE: CR-14x17 Cassette or DR detector

CENTRAL RAY:

PA/AP: Perpendicular to T-7 (7-8" below vertebral prominence)

HELPFUL POSITIONING:

1. Take requested side down.
 - a. Left Lateral Decubitus: Left side down.
 - b. Right Lateral Decubitus: Right side down.
2. Have patient raise arms high above their head to keep upper arm out of lung field.

ADDITIONAL COMMENTS:

1. Make certain to label and mark the image properly.
2. Make sure patient is straight. Patient cannot be rotated for this view.

CHEST FOR LEADLESS PACEMAKER PORTABLE

ROUTINE: Portably: AP Chest done bedside. Patient is to remain flat for 4hrs after surgery.

DO NOT SIT UP at this point.

DISTANCE: 48"

BUCKY: NO- *Use a Grid*

FOCAL SPOT: Large

IMAGING PLATE: DR detector

CENTRAL RAY:

AP: Perpendicular to T-7 (7-8" below vertebral prominence)

CHEST FOR LEADLESS PACEMAKER IN DEPARTMENT

-Done as a normal PA and Lateral with no restrictions on how high the patient can raise arms.

IMG1130 XR CHEST 1 VIEW (SPECIFY SPECIAL VIEW)

CHEST-APICAL LORDOTIC

ROUTINE: Apical Lordotic view.

DISTANCE: 72"

BUCKY: Yes

FOCAL SPOT: Large

IMAGING PLATE: CR-14x17 Cassette or DR detector

CENTRAL RAY:

AP: Perpendicular to mid-sternum.

HELPFUL POSITIONING:

Place patient in the AP position with their back against the Upright Bucky. Hands are on their hips. Have patient walk forward 1 1/2 feet until only their shoulders are touching the Upright Bucky. Arch the back to produce a good lordotic chest. If patient is unable to do so, you must compensate by angling the tube. Place top of image receptor at least 2" above shoulders.

IMG1179L LEFT XR RIBS
IMG1179R RIGHT XR RIBS
IMG11672L LEFT XR RIBS AND CHEST (1 VIEW)
IMG11672R RIGHT XR RIBS AND CHEST (1 VIEW)
IMG1178 XR RIBS BILATERAL
IMG11672B XR RIBS BILATERAL AND CHEST (1 VIEW)

RIBS

ROUTINE: AP Upper and Lower Ribs of affected side & 25-30° Obliques of Upper and Lower Ribs of affected side for a total of 4 views. Each side is done separately. If Bilateral Ribs are ordered, 8 views are done. A PA Chest may be included, if ordered.

DISTANCE: 40"

BUCKY: YES

FOCAL SPOT: Small

IMAGING PLATE: 14x17 CR cassettes or DR detector-be sure to overlap

CENTRAL RAY:

Upper Ribs: Perpendicular to the image receptor centered on T-7 (3-4" below jugular notch). Center the side affected on the image receptor.

Lower Ribs: Perpendicular to the image receptor centered to midway between xyphoid and lower rib cage. Center the side affected on the image receptor.

HELPFUL POSITIONING:

Upper Ribs: Patient is AP. AP and Oblique Upper ribs done on inspiration. Include the first rib. Either RPO or LPO depending on affected side.

Lower Ribs: Patient is AP. AP and Oblique Lower ribs done on expiration. Include the 12th rib. Either RPO or LPO depending on affected side.

ADDITIONAL COMMENTS:

When marking rib images, be sure to mark the anatomical side correctly. For example - if you are imaging the left ribs, use your left marker and place it on the left side of the patient.

IMG1122 XR STERNUM 2+ VIEWS

STERNUM

ROUTINE: RAO and Lateral.

DISTANCE: 30" to 40" for the RAO, 72" for the Lateral

BUCKY: YES

FOCAL SPOT: Large

IMAGING PLATE: 10x12 CR cassettes or DR detector

CENTRAL RAY:

RAO: Perpendicular to the image receptor centered on mid-sternum.

Lateral: Perpendicular to the image receptor centered to mid-sternum.

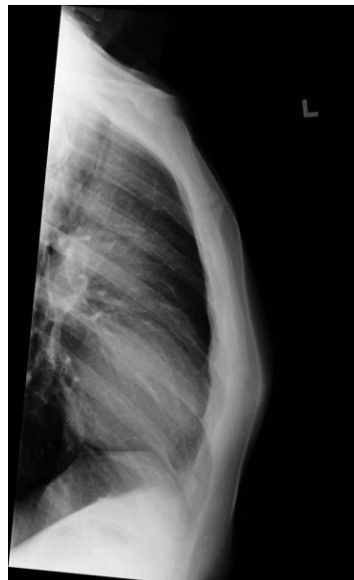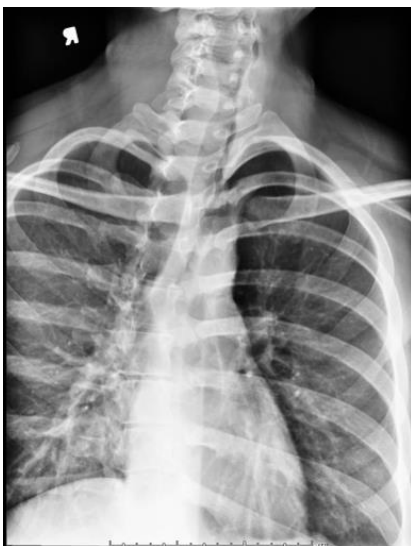HELPFUL POSITIONING:

RAO: Oblique patient 15-20° to the right. Align the long axis of sternum to midline of table or bucky. Place top of the image receptor 1 1/2" above the jugular notch. Use 30-40".

Lateral: Patient lying on side or left side against bucky. Use 72" SID to reduce magnification of sternum.

ADDITIONAL COMMENTS:

1. Patient is obliqued RAO to visualize sternum over the heart.
2. Lateral: Try and get the patient to throw their shoulders back and stick out their chest.



STERNOCLAVICULAR (SC) JOINTS

ROUTINE: PA & Bilateral Anterior Obliques (Both obliques done for comparison.)

DISTANCE: 40"

BUCKY: Yes

FOCAL SPOT: Small

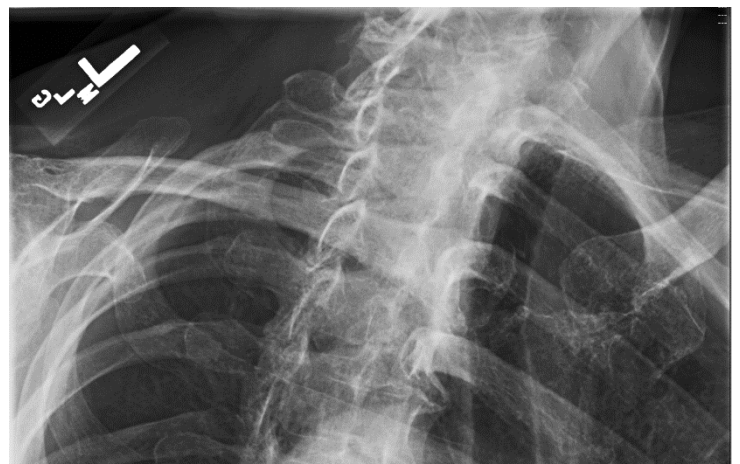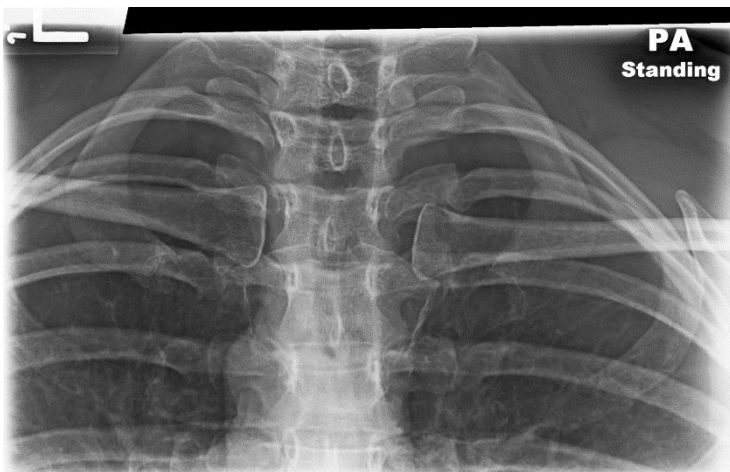IMAGING PLATE: 8x10 CR cassettes or DR detector

CENTRAL RAY: *PA:* 3" inferior to the C7 spinous process, perpendicular to midsagittal plane.

Obliques: 3" inferior to the C7 spinous process, 1-2" lateral to midsagittal plane (toward elevated side).

HELPFUL POSITIONING:

1. *PA:* Patient prone or erect. Rest patient's arms along sides of body with palms facing posteriorly to bring SC joints closer to the image receptor. Adjust patient's head and chin to eliminate body rotation.
2. *Obliques:* Patient prone or erect. Rotate patient 10-15 degrees to shift vertebrae away from sternum (best visualizes **downside** SC joint). **RAO** will demonstrate the right SC joint. **LAO** will demonstrate the left SC joint.
3. All views done on expiration for more uniform density.



ABDOMEN WITH CONTRAST (GASTRIC FEEDING TUBE CHECK)

Abdomen images are done to confirm placement of a chronic feeding tube.

ROUTINE: Abdomen x-ray is done after the patient is given contrast (Omnipaque/Omni 300) by injection via feeding tube or G-tube. ***This is not a fluoroscopy procedure.***

DISTANCE: 40"

BUCKY: YES or Grid if ordered to be done as a Portable.

FOCAL SPOT: Large

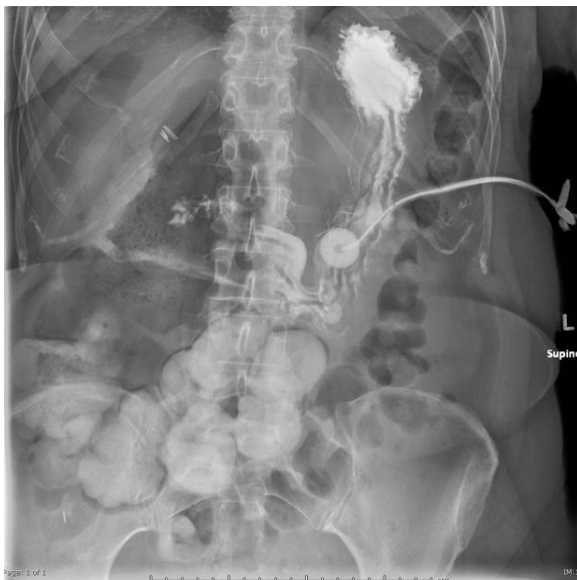IMAGING PLATE: 16x16 detector or 14x17 CR Cassette.

CENTRAL RAY: Perpendicular to the image receptor centered at level of the iliac crests with bottom of the image receptor at the pubic symphysis.

SEQUENCE: Provider orders an “Abdomen with Contrast” after G-tube replacement. For adults, obtain 30 mL of Omnipaque from Fluoro. For small children, ask a radiologist. Confirm that the patient does not have any allergies, particularly iodine or iodine products before administering contrast. If patient has an iodine allergy, thin barium can be used provided the G-tube does not have a small diameter that could get clogged. Contrast is injected into G-tube by a nurse, provider, or technologist. Obtain an abdomen x-ray immediately after the contrast is injected. Flush the G-tube with 10 mL of saline so the tube doesn’t get clogged. (Wait until after image is taken so contrast is not diluted.)

IN EPIC: At “Begin Exam”, the technologist orders the contrast in the MAR.

At “End Exam”, track what was given, the time it was given, and the amount given.



The picture to the left is an example of a G-tube check. If the patient has a J-tube the contrast will/should flow into the small bowel (jejunum) vs. the stomach.

IMG1100 XR ABDOMEN 1 VIEW
IMG1101 XR ABDOMEN 2 VIEW

ABDOMEN/KUB

ROUTINE: KUB-to include Kidneys, Ureters & Bladder

1View ABDOMEN-Supine Abdomen to include flank to flank and symphysis.

2View ABDOMEN-Supine Abdomen to include flank to flank and symphysis **and Upright Abdomen** to include flank to flank **and** diaphragm down to the pubic symphysis.

Abdomen images done for POST EVAR (endovascular surgery for AAA repair)-ordered by Dr. Sig, Cogbill or Clark-take 1 exposure on a 14x17 lengthwise to visualize graft.

Diaphragms and/or symphysis not needed.

DISTANCE: 40"

BUCKY: YES

FOCAL SPOT: Large

IMAGING PLATE: DR detector or 14x17 CR Cassette.

CENTRAL RAY: Perpendicular to the image receptor centered at level of the iliac crests with bottom of the image receptor at the pubic symphysis.

HELPFUL POSITIONING:

1. Be certain to include the entire abdomen (flank to flank) for anything other than a KUB. Take two images and possibly a 3rd if necessary.
2. If ordered for ***Aneurysm***, do an LPO and a Lateral.
3. If unable to do upright, do a Left Lateral Decubitus.
4. Up to 3 yrs old, if patient can't stand, do Left Lateral Decubitus Abdomen (left side down) rather than sitting Abdomen.

When sending an abdomen done in Litho, charge IMG1100A XR ABDOMEN DONE IN SURGERY (reference image only).

IMG1630AD

SMALL BOWEL SERIES - GASTROVIEW ADHESIVE OBSTRUCTION

ROUTINE: Abdomen x-rays are done in timed intervals after the patient is given Gastroview.

DISTANCE: 40"

BUCKY: YES

FOCAL SPOT: Large

IMAGE RECEPTOR: 16x16 or 14x17 detector

CENTRAL RAY: Perpendicular to image receptor centered at level of the iliac crests with bottom of the IR at the pubic symphysis.

SUPPLIES NEEDED:

- 50 mL cath syringe
- 90 mL (3 bottles) Gastroview
- 30 mL water

NOTE: Syringes and cups are stocked right next to the Gastroview on the fluoro cart. There is a key for the cart in TEC and one in the top file drawer in Fluoro (the key has a pine tree on it).

PATIENT SAFETY:

- **Confirm the patient does Not have an Iodine Allergy.**
 - If the patient has an iodine allergy listed, the ordering provider should consult the radiologist who is on for the shift. The patient may, or may not, need premedication.
 - If the radiologist and provider agree that the exam can still be performed after the patient is premedicated, a nurse should be present during the administration of contrast.
 - Nursing options include-
 - Ask the nurse to come down to the department with the CNA to be present while the contrast is administered by the technologist or the nurse, OR
 - Have the patient come down to the department for their initial images to evaluate tube placement, which is verified by a radiologist. If the tube is in the correct position, the contrast can be sent back to the floor for administration by the patient's nurse, or the technologist can travel up to the floor and administer the contrast in the patient's room with the nurse present.
- **Check if the patient has an NG tube.** If so, it should be running on suction for *at least 2 hours* prior to administering contrast. If the patient does not have an NG tube, verify that they are not an aspiration risk.

Continued on next page

POST-CARE INSTRUCTIONS:

- Tell the CNA who is transporting the patient – Do NOT hook suction back up until after the procedure is complete.
- Call the floor and let the patient's nurse know what time the contrast was administered. Additional post-care instructions will be in the nursing care orders.

EXAM SEQUENCE:

1. Take scout image of the upper and lower abdomen - include from symphysis upward to NG tube (you do not need to get entire bowel side-to-side).
 - a. **If no scout image it taken:** when ending the exam in the notes section make sure to document why a scout wasn't obtained and what time the contrast was administered so the radiologist knows when it was given. An example of why it a scout wasn't obtained could be because the patient had an abdomen exam earlier in the day and the radiologist ok'd the previous image prior to contrast being given.
2. Have a radiologist confirm NG tube placement before giving contrast. Ask ordering surgeon if radiologist unavailable.
3. Administer contrast.
 - a. If the patient has an NG tube, push 90 cc of Gastroview through the NG and then flush with 30 cc of water.
 - b. If patient does NOT have an NG tube, have them drink the Gastroview. You may give up to 90 cc of water with it to help wash it down.
4. Take 4-hour images of abdomen - include entire bowel.
5. After the 4-hour images, text-page the ordering provider to review. ***If after 1700 hrs, page attending provider or on-call resident to review images.***
6. If you do not hear back from the provider with further instructions, get 8-hour images and end the study. ***If it is after hours, the second set of images can wait until the following AM to be done.***

IN EPIC:

- At "Begin Exam", the technologist orders and administers the contrast in the MAR.
- At "End Exam", verify contrast administration was documented. Exam should not be ended until the last image is taken.

La Crosse Technologists:

Paging the on-call resident after hours-

- Gladiator
- On-call/paging
- In the search bar type in "surgery"
- Look for the surgery department folder on the left side of the screen
- Select the folder listed "surgery (floor call) Acute care services"
- Select and page the resident who is on for the shift.

BABYGRAM

ROUTINE: AP Chest and Abdomen with 1 exposure.

DISTANCE: 40"

BUCKY: NO

FOCAL SPOT: Small

IMAGING PLATE: CR-8x10 or 10x12 or DR detector

CENTRAL RAY: Perpendicular to the image receptor centered on abdomen-to include abdomen and all of chest.

HELPFUL POSITIONING:

Image must include chest and abdomen with a technique suitable for the abdomen yet doesn't "burn out" the lung fields. Done AP @ 40". Hold baby with arms above the head and legs straight down.

ADDITIONAL COMMENTS:

Use a "Tame-em-Board" if one is available or use sponges, sandbags, and tape to immobilize the child. If parents are with the child, instruct them on how to adequately hold them.

BABYGRAM STILLBORN

ROUTINE: AP entire body with baby in as much of an anatomical position as possible. This may take multiple exposures depending on the size of the baby.

DISTANCE: 44"

BUCKY: NO

FOCAL SPOT: Small

IMAGING PLATE: CR-8x10 or 10x12 or DR detector.

CENTRAL RAY: To include entire head and all extremities. If two images are required, take one from the head down and one from the feet up.

ADDITIONAL COMMENTS: Have nurse position baby.

NOSE TO RECTUM FOR FOREIGN BODY (BODY FOR FOREIGN BODY – INFANT)

ROUTINE: AP of a child that includes from their nose to the rectum. Done when looking for a foreign body and not sure where it is. This exam can be done on any child that will fit on one image, regardless of age. If the child is too large to fit on one image, chest and/or abdomen exams should be ordered separately.

DISTANCE: 40"

BUCKY: NO

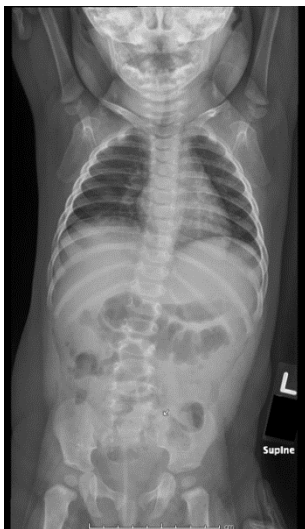
FOCAL SPOT: Small

IMAGING PLATE: CR-14x17 or DR detector

CENTRAL RAY: Perpendicular to the image receptor centered mid-abdomen to include as much of the child as possible. The top of the image receptor is just above their nose.

HELPFUL POSITIONING: Image must include from the nose, the entire chest and abdomen, down to the pubic symphysis with a technique suitable for the abdomen yet doesn't "burn out" the lung fields. Done AP at 40". Hold child with arms above the head and legs straight down.

ADDITIONAL COMMENTS: Use a "Tame-em-Board" if one is available or use sponges, sandbags, and tape to immobilize the child. If parents are with the child, instruct them on how to adequately hold them.



IMG1104 XR CERVICAL SPINE 2-3 VIEWS
IMG1105 XR CERVICAL SPINE MINIMUM 4+ VIEWS
IMG 1290 XR CERVICAL SPINE 6-7 VIEWS

CERVICAL SPINE

ROUTINE: AP, Lateral & Odontoid.

Pediatric routine: **NO** Odontoid view on patients under 2yrs.

DISTANCE: 40" for AP and Odontoid.

72" for Upright Lateral.

BUCKY: YES

FOCAL SPOT: Small

IMAGING PLATE: CR-10x12 cassettes for AP and Lateral, 8x10 for Odontoid View or DR detector for all.

CENTRAL RAY:

AP: 10-15° cephalic angle entering at the superior border of the thyroid cartilage.

Lateral: Perpendicular to the image receptor entering the side of the neck at the level of the thyroid cartilage.

Odontoid: Perpendicular to the image receptor entering through the open mouth. **NOT DONE on patients under 2yrs.**

ADDITIONAL COMMENTS:

1. Per radiologists and neurosurgeons, use sandbags to lower shoulders for the lateral view on all non-trauma patients. This includes patients with known fractures that are presenting for follow-up imaging. All of C-7 must be visualized or a Swimmers View must be taken.
2. ***In the case of trauma***, we do not need to have a physician clear the lateral, just use spinal precautions with as little movement as possible. Do **NOT** remove collars unless films have been checked by physician.
3. Remember to try and remove as much of the foreign bodies (oxygen tubing, monitor leads, earrings, hair clips) as possible to obtain a better image.
4. For spines ordered portably-only give two good attempts then plan to take patients to CT.

SEE ALSO/OTHER VIEWS:

1. Fuchs for odontoid tip-done AP with chin tipped up-central ray entering at the chin.
In the case of trauma angle parallel with the jaw line-central ray entering at chin.
2. For Atlanto-axial Instability: Lateral, Open Mouth, Flexion, and Extension

[Go to "Cervical Spine-Flexion/Extension"](#)

[Go to "Cervical Spine-Obliques"](#)

CERVICAL SPINE-FLEXION/EXTENSION

ROUTINE: Flexion and Extension views of lateral neck.

DISTANCE: 72"

BUCKY: YES

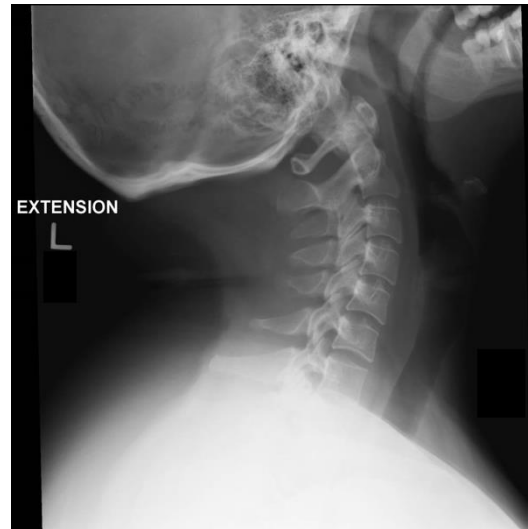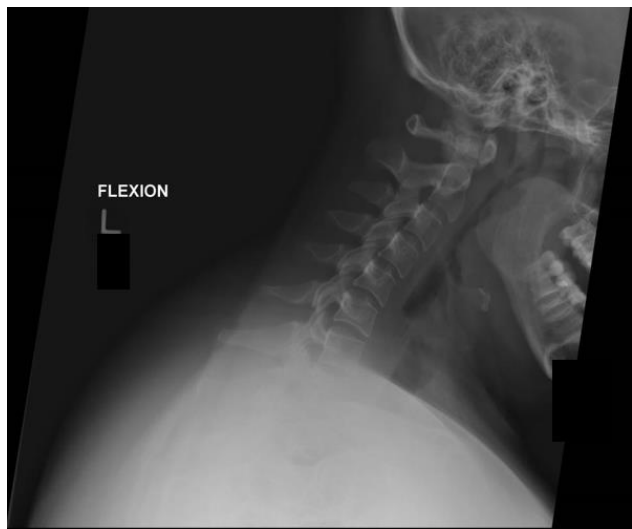
FOCAL SPOT: Small

IMAGING PLATE: 10x12 CR cassette or DR detector.

CENTRAL RAY: Perpendicular to the image receptor entering the side of the neck at the level of the superior border of the thyroid cartilage.

ADDITIONAL COMMENTS:

1. **DO NOT ATTEMPT** these for a new injury unless the doctor has checked the routine images first and they are cleared.
2. Mark images with appropriate flexion/extension markers.
3. **ER/Urgent Care:** If preliminary images are not yet cleared by Radiologist, consult ordering physician before positioning the flexion/extension images.



CERVICAL SPINE-OBLIQUES

ROUTINE: Bilateral Obliques (usually taken in conjunction with routine cervical spine).

DISTANCE: 40"

BUCKY: YES

FOCAL SPOT: Small

IMAGING PLATE: 10x12 CR cassette or DR detector.

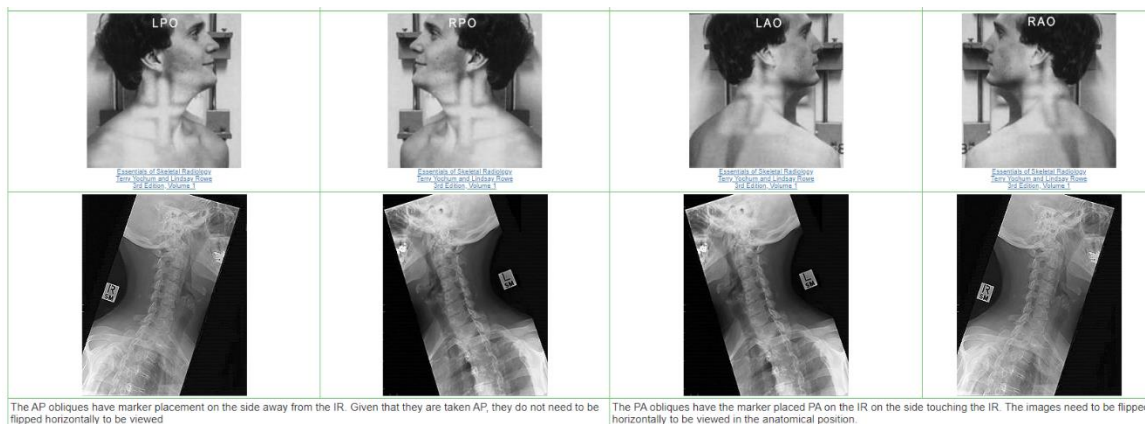
CENTRAL RAY: If done AP, angle tube 15° cephalic. If done PA, angle tube 15° caudal entering at level of the superior border of the thyroid cartilage.

HELPFUL POSITIONING:

Obliques: Angle patient 45° with head in line with the body.

ADDITIONAL COMMENTS:

Please mark the side of interest as shown in images below. LPO and RPO projection is preferred, but not required. If doing LPO and RPO, mark the side UP. If doing LAO or RAO projection, flip marker PA and mark the side DOWN. PA images should also be flipped to be viewed in anatomical position. It is not necessary to annotate which oblique was done.



CERVICAL THORACIC SPINE

ROUTINE: AP, Lateral, and Swimmers View done standing. Include entire cervical spine down to T7.

DISTANCE: AP and Lateral done at **48"** – Swimmers done at 40"

BUCKY: YES

FOCAL SPOT: Large

IMAGING PLATE: 14x17 CR Cassette or DR detector.

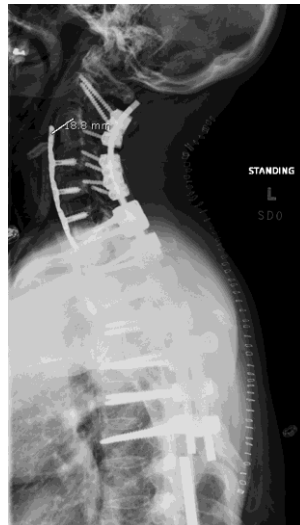
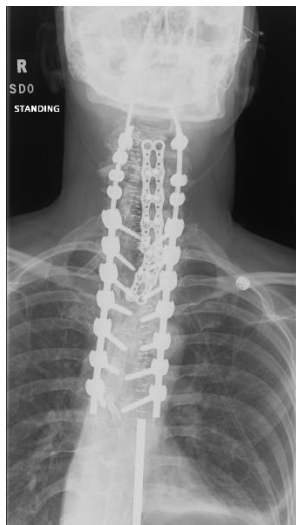CENTRAL RAY:

AP and Lateral: Perpendicular to the image receptor. No tube angle.

POSITIONING: The top of the image receptor is placed at the top of the ear.

ADDITIONAL COMMENTS:

1. Include C-1 on Swimmers View.
2. No odontoid view needed.
3. Process images under Thoracic Spine.



IMG1190 XR THORACIC SPINE 3 VIEWS (ROUTINE ORDER TO INCLUDE SWIMMERS VIEW)
IMG1189 XR THORACIC SPINE 2 VIEWS
IMG1275 XR THORACIC SPINE 4-5 VIEWS WITH OBLIQUES

THORACIC (DORSAL) SPINE

ROUTINE: AP, Lateral, and Swimmers View.

DISTANCE: AP and Lateral done at **44"** – Swimmers
done at 40"

BUCKY: YES

FOCAL SPOT: Large

IMAGING PLATE: CR-14x17 Cassette or DR detector.

CENTRAL RAY:

AP and Lateral: Perpendicular to the image receptor entering at the midline
at the level of 3" inferior to the sternal notch.

ADDITIONAL COMMENTS:

1. Done on inspiration.
2. Bilateral Obliques taken only upon request. Rotate patient 10° back and forward off Lateral position.
3. Include C-1 on Swimmers View.

Neurosurgeons and chiropractors want all spines done standing, unless otherwise noted.

The lateral is to be done with equal weight on both feet. Cross arms in front of the body with hands on shoulders.

ALL STANDING T-SPINES SHOULD BE DONE WITH SHOES OFF.

THORACOLUMBAR SPINE

ROUTINE: AP & Lateral spine from level of *T6-7 to L4*.

DISTANCE: 44"

BUCKY: Yes.

FOCAL SPOT: Large.

IMAGING PLATE: 14x17 CR Cassette or DR detector.

CENTRAL RAY:

AP & Lateral: Perpendicular to the image receptor.

POSITIONING: The bottom of the image receptor is placed at the level of the

Iliac Crests (L5 will not be included). A separate Lumbar spine should be

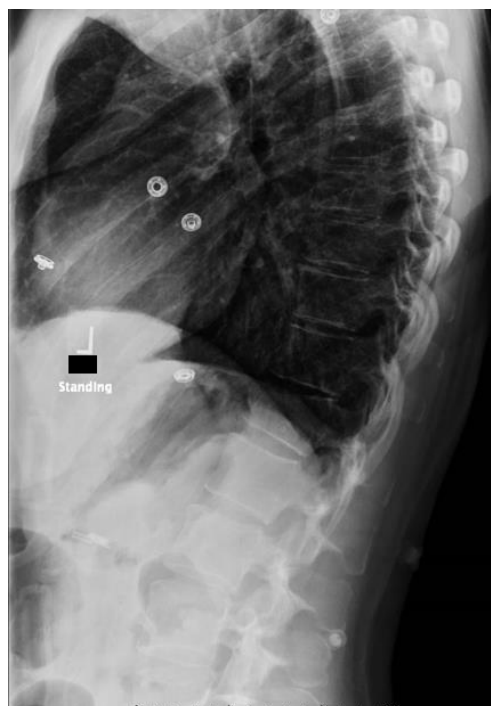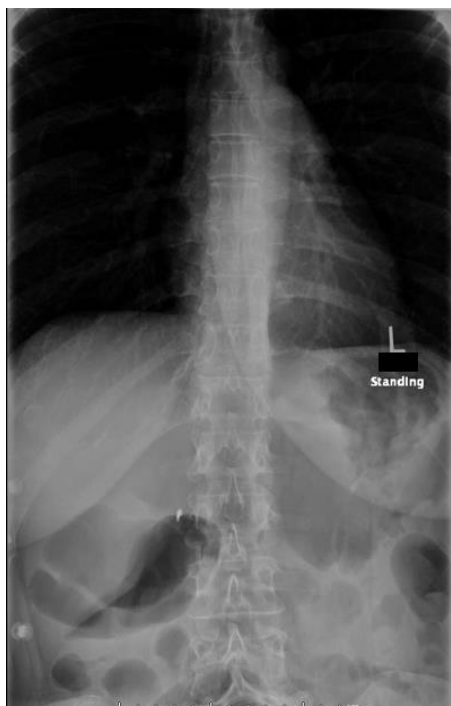Ordered if the entire Lumbar spine is needed.

ADDITIONAL COMMENTS: this is also known as DORSOLUMBAR SPINE.

Neurosurgeons and chiropractors want all spines done standing, unless otherwise noted.

The lateral is to be done with equal weight on both feet. Cross arms in front of the body with hands on shoulders.

***ALL STANDING THORACOLUMBAR SPINES SHOULD BE DONE WITH SHOES OFF. ***



IMG1108 XR LUMBAR SPINE 2-3 VIEWS
IMG1177 XR LUMBAR SPINE 4-5 VIEWS
IMG1273 XR LUMBAR SPINE 6-7 VIEWS WITH BENDS/OBLIQUES

LUMBOSACRAL SPINE

ROUTINE: AP, Lateral, and Lateral Cone down of L-5/S-1 joint.

Peds Routine: No spot image on children under 16 years of age.

DISTANCE: 40"

BUCKY: YES

FOCAL SPOT: Large

IMAGING PLATE: 14x17CR cassettes, 8x10 for Spot or DR detector

CENTRAL RAY:

AP and Lateral: Perpendicular entering the midline at the level of 1 1/2" above the iliac crest.

L-5/S-1 Spot: 5-7° caudal angle needed entering at a point 1 1/2" inferior of the crest and 1 1/2" posterior the ASIS.

HELPFUL POSITIONING:

Lateral: Leave collimators open on all laterals done on patients age 40 or above to demonstrate any possibility of calcified abdominal aorta.

Obliques: Taken bilaterally. Done AP. Roll patient 45°. Label side closest to the image receptor. This demonstrates apophyseal joint of that side and SI joint of opposite side.

Trauma: X-table lateral may be needed in event of trauma. No spot is done for trauma.

Neurosurgeons and chiropractors want all spines done standing, unless otherwise noted.

The lateral is to be done with equal weight on both feet. Cross arms in front of the body with hands on shoulders.

All Standing L-spines should be done with shoes off

LUMBOSACRAL SPINE F/U ARTHROPLASTY

(ORDERED BY NEUROSURGERY)

ROUTINE: Standing AP Entire Lumbar Spine, Coned Down Lateral in Neutral Position,
Supine Coned Down Ferguson.

DISTANCE: 40"

BUCKY: YES

FOCAL SPOT: Large

IMAGING PLATE: 14x17 CR cassettes, 10x12 for Spot or DR detector

CENTRAL RAY:

AP Standing Entire Lumbar: Perpendicular entering the midline at the level of 1 1/2" above the crest.

Coned Down Laterals: Perpendicular entering at the level of the arthroplasty.

AP Supine Ferguson View: 30-degree cephalic tube angle centered at the arthroplasty.

HELPFUL POSITIONING:

AP: Patient should be standing straight and not leaning to one side.

Ferguson View: Patient must be centered on the table, laying as flat as possible. Would like to see spinous processes straight along with "fin" of the arthroplasty.

If there is more than one arthroplasty, do a separate Ferguson View at each level.

If patient has had multiple arthroplasties, center at middle arthroplasty on Lateral View.

IMG1188 XR SCOLIOSIS 1 VIEW
IMG1192 XR SCOLIOSIS 2 VIEWS

SCOLIOSIS

ROUTINE: AP OR PA and Lateral. *Scoliosis exams should only be done at sites that have a long scoliosis cassette or that can stitch DR images. *

DISTANCE: 60", 72" or 84" - depending on the size of patient

BUCKY: YES

FOCAL SPOT: Large

IMAGING PLATE: CR Scoliosis Cassette or Stitched DR images

CENTRAL RAY: Perpendicular to the image receptor centered on mid entire spine.

HELPFUL POSITIONING:

AP/PA-Make sure patient removes shoes, place them PA/AP, top of image receptor above top of ear. Need to see SI joints. Chin up slightly.

Lateral-Left Lateral. Arms straight out at 90° to body. Use lateral filter. Measure through the lower T-Spine area for both views.

ADDITIONAL COMMENTS:

1. First time exam-Do AP standing-no shielding
2. All follow up exams do PA standing.

Dr. Hughes-

AP – Even weight on both legs, with patient standing up straight. Wants to see top of crest and acetabulum. Make sure you can see the spine through the abdomen. If light, repeat. Dr. Hughes will window/level if the t-spine is dark.

Lat – Have patient stand straight up, knees locked, and arms crossed with hands touching clavicles.

*No matter if the patient is AP or PA always send the images PA-left on left.

SCOLIOSIS – BEND VIEWS

ROUTINE: AP side bend views. *Scoliosis exams should only be done at sites that have a long scoliosis cassette or that can stitch DR images.*

DISTANCE: 60", 72" or 84" - depending on the size of patient

BUCKY: YES

FOCAL SPOT: Large

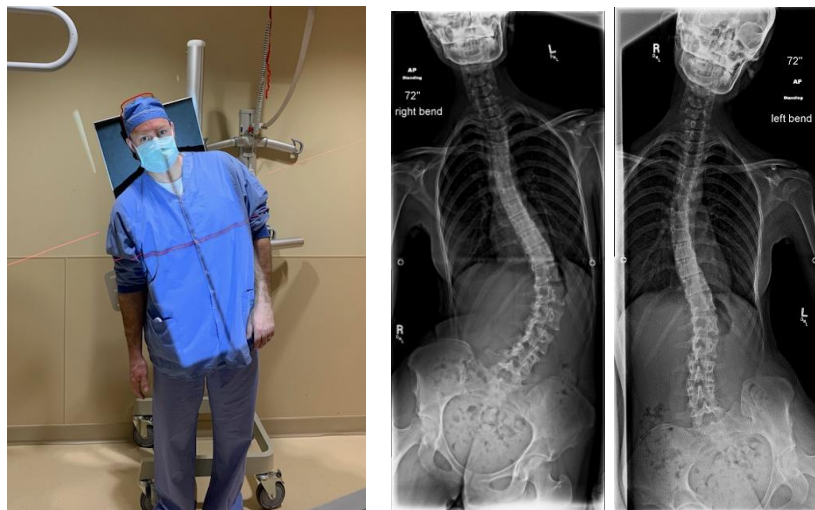
IMAGING PLATE: CR Scoliosis Cassette or Stitched DR images

CENTRAL RAY: Perpendicular to the image receptor centered on mid entire spine.

HELPFUL POSITIONING: Make sure patient removes shoes. Position them AP with top of image receptor above top of ear. Need to see SI joints. Chin up slightly. Have patient bend sideways, reaching for side of knee. Measure through the lower T-Spine area.

ADDITIONAL COMMENTS:

1. Do both left and right bends.
2. If patient is very flexible, you may need to tilt image receptor diagonally to include entire spine.



ENTIRE SPINE-PRE ECT WORK UP

ROUTINE: AP and Lateral Cervical, Thoracic, and Lumbar Spine—no Spot images

DISTANCE: 40"

BUCKY: YES

FOCAL SPOT: Large

IMAGING PLATE: Use appropriate size CR cassettes or DR detector

CENTRAL RAY: See each separate exam.

[Go to Cervical Spine](#)

[Go to Thoracic Spine](#)

[Go to Lumbar Spine](#)

IMG1238R RIGHT XR CLAVICLE 1-2 VIEWS
IMG1238L LEFT XR CLAVICLE 1-2 VIEWS

CLAVICLE

ROUTINE: AP----*Axial (25° cephalic) only taken if possible fracture seen.*

Ortho routine AP, 30-degree cephalad and 30-degree caudad.

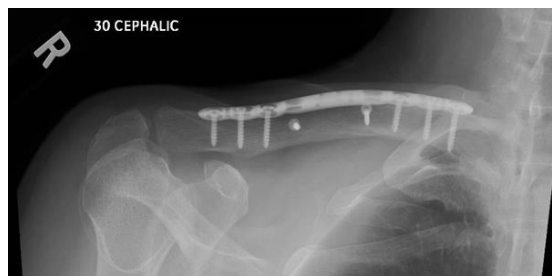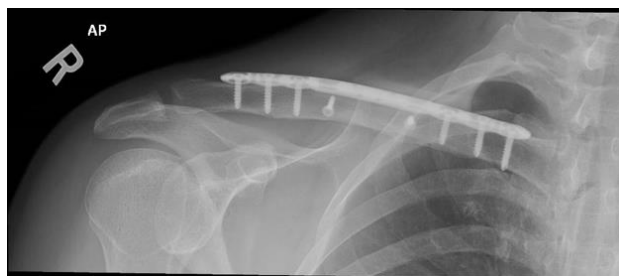DISTANCE: 40"

BUCKY: Yes

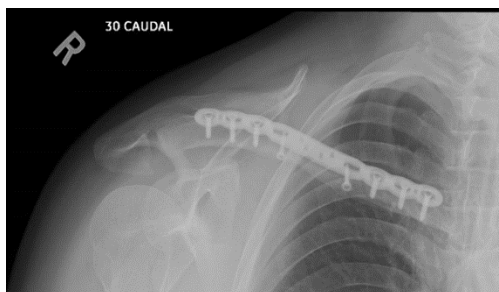
FOCAL SPOT: Small

IMAGING PLATE: 10x12 CR cassette or DR detector

CENTRAL RAY: Perpendicular to mid-clavicle.



30-degree caudal
images only taken if
requested by ortho-
not part of the
routine views
performed



IMG1102 XR AC JOINTS WITH AND WITHOUT WEIGHTS

ACROMIO-CLAVICULAR JOINTS

ROUTINES: AP of both shoulders, coned down to the AC joint-separate exposures-with & without weights (4 exposures).

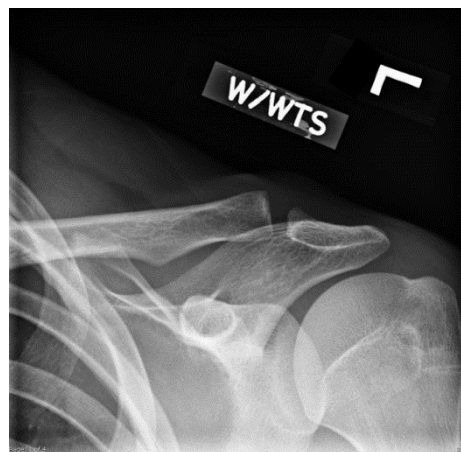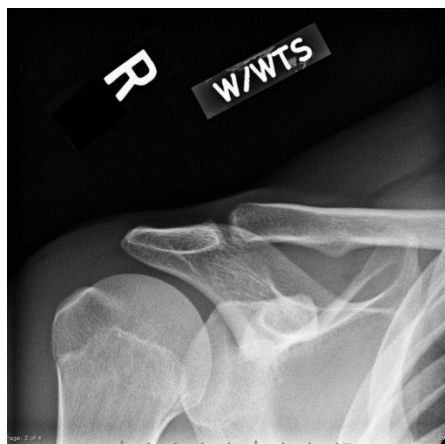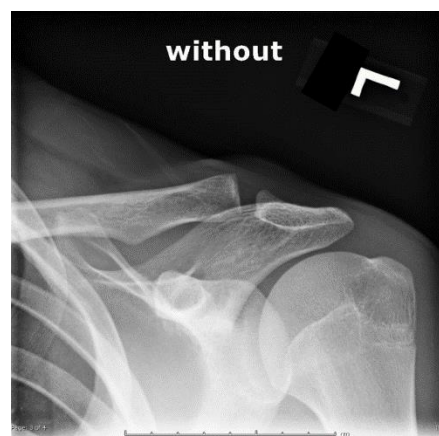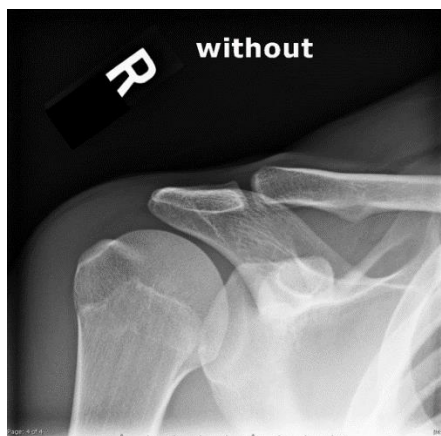DISTANCE: 40"

BUCKY: Yes

FOCAL SPOT: Small

IMAGING PLATE: 8x10 CR cassette or DR detector

CENTRAL RAY: Perpendicular to the AC joints.



IMG1198L LEFT XR UPPER EXTREMITY INFANT 2+ VIEWS
IMG1198R RIGHT XR UPPER EXTREMITY INFANT 2 VIEWS

INFANT UPPER EXTREMITY

ROUTINE: *AP and Lateral* view of upper extremity including shoulder joint to wrist joints.

One single image is taken for each view.

DISTANCE: 40"

BUCKY: NO

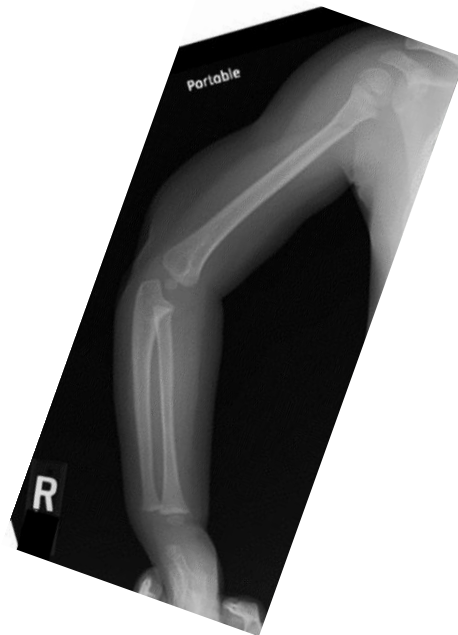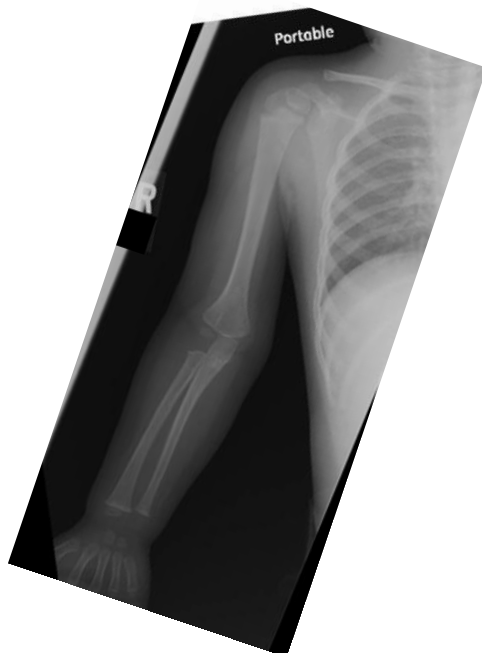FOCAL SPOT: Small

IMAGING PLATE: Appropriately sized CR Cassette or DR detector

CENTRAL RAY: Perpendicular to the image receptor centered at the elbow joint.

ADDITIONAL COMMENTS:

1. Ordered for when child is ***under 1 year old*** to include entire upper extremity on 1 image.
2. If patient tolerates, a lateral image is done by bending the upper extremity at the elbow joint to place it in a lateral position.



IMG1186L LEFT XR SHOULDER 2+ VIEWS
IMG1186R RIGHT XR SHOULDER 2+ VIEWS

SHOULDER

ROUTINE: **TRAUMA/INJURY:** AP, Grashey & Axillary.

PAIN – NO INJURY:

Age 18+ - AP, Grashey, Outlet & Axillary.

< Age 18 - AP, Outlet & Axillary.

DISTANCE: 40”

BUCKY: Yes for AP, Outlet & Grashey. No for Axillary.

FOCAL SPOT: Small or Large

IMAGING PLATE: 10x12 CR Cassette or DR detector

CENTRAL RAY:

1. **AP & Grashey:** Perpendicular to coracoid process.
2. **Outlet:** 10° caudal angle centered to the shoulder joint.
3. **Axillary:** Perpendicular to the image receptor through the axilla region.

HELPFUL POSITIONING:

1. **AP:** the entire clavicle is no longer required- include the lateral ½ to 2/3 of the clavicle. Arm should be placed in neutral position, unless specified otherwise on order.
2. **Grashey (AP Neer):** 30° oblique of patient toward affected side.
3. **Outlet:** 10° caudal angle. Patient is PA and obliques about 45°. Draw an imaginary line between the vertebral body of the scapula & the coracoid. This should be perpendicular with the image receptor. Patient should be standing straight up with shoulders back.
4. **Axillary:** Have the patient hold an IV pole or put a sponge under their arm to bring the arm straight out. A x-table axillary is the preferred method. However if equipment (floor mount tubes) or patient condition does not allow for this, a superior-inferior view may be taken. *A grid may be needed on larger patients if the image is noisy due to scatter. On small pediatric patients where an axillary is not possible the provider should either consult the radiologist or should order a clavicle and humerus images.*

SEE ALSO/OTHER VIEWS:

1. **Scapular Y (PA Neer):** Same as Outlet, but no tube angle.
2. **Coracoid Process View:** Performed in AP position. Angle tube 20-30 degrees cephalic and cone down to coracoid.

GARTH METHOD (AP APICAL OBLIQUE AXIAL) SHOULDER (COMMONLY ORDERED BY MIKE LUTER)

DISTANCE: 40"

BUCKY: Yes

FOCAL SPOT: Small or Large

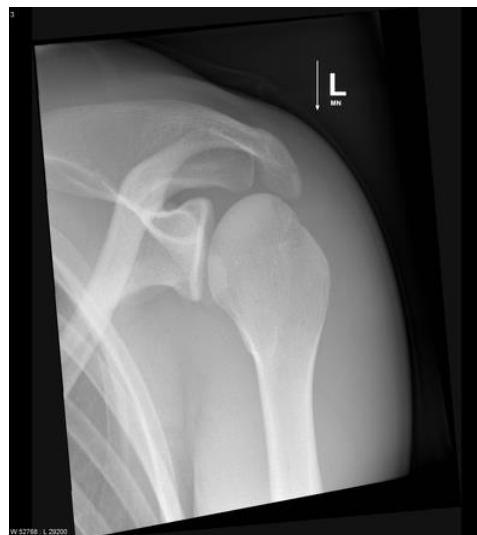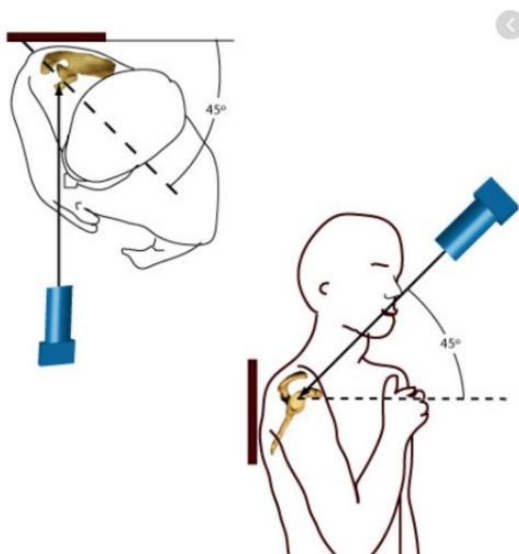
IMAGING PLATE: 10x12 CR Cassette or DR detector

PATIENT POSITIONING: Can be performed erect or supine. Place the patient in an AP position and rotate patient's body 30-45-degrees toward the affected side. Ideally the patient wants to have the affect side's hand resting on the unaffected shoulder (gently reaching across body).

CENTRAL RAY: Angle 45-degrees caudal centering at the scapulohumeral joint.

IMAGE EVALUATION:

1. Humeral head will appear elongated
2. The coracoid process will sometimes be projected over the humeral head
3. The AC joint should be superior to humeral head.
4. If the patients' shoulder is posteriorly displaced, the humeral head will be projected superior to the glenoid obstructed by the acromion.
5. If the patients' shoulder is anteriorly displaced, the humeral head will be projected inferior to the glenoid.



STRYKER “NOTCH” METHOD (AP AXIAL PROJECTION) (COMMONLY ORDERED BY MIKE LUTER)

DISTANCE: 40”

BUCKY: Yes

FOCAL SPOT: Small or Large

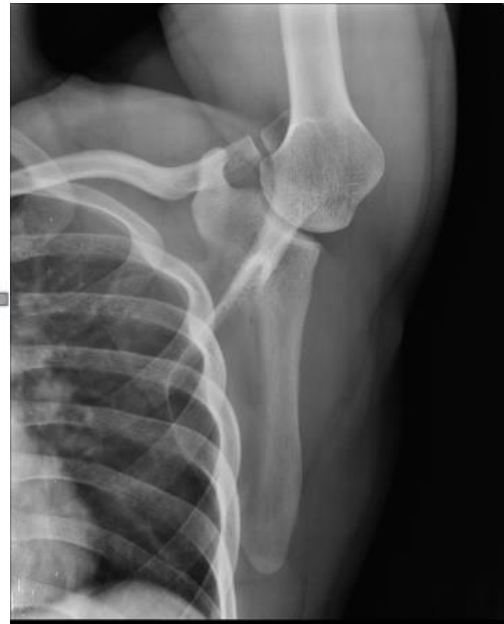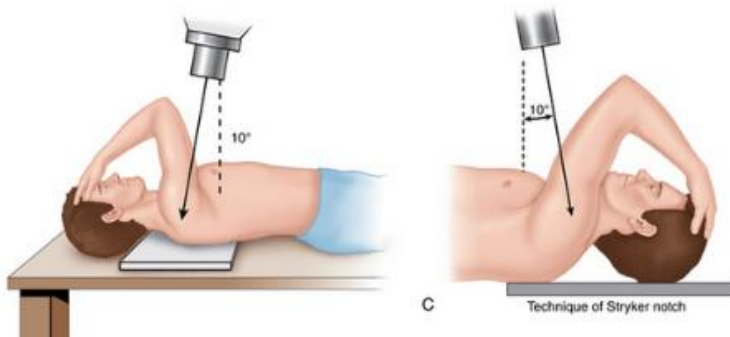
IMAGING PLATE: 10x12 CR Cassette or DR detector

PATIENT POSITIONING: Patient will be in a supine position on the table. Have patient flex the affected arm slight more than 90-degrees. Then have them place their palm on top of their head (this will place the humerus in a slightly internal rotation). Image receptor should be in the table bucky.

CENTRAL RAY: Angle the central ray 10-degree cephalic, entering at the coracoid process.

IMAGE EVALUATION:

1. The glenohumeral joint should be open.
2. The humerus is pointing superiorly.
3. The lateral portion of the humeral head should be free of superimposition.



VELPEAU AXILLARY SHOULDER

DISTANCE: 40"

BUCKY: No (grid may be needed on larger patients like a normal axillary view)

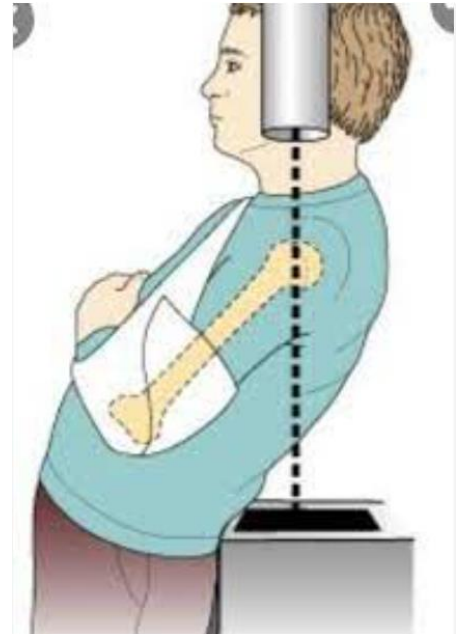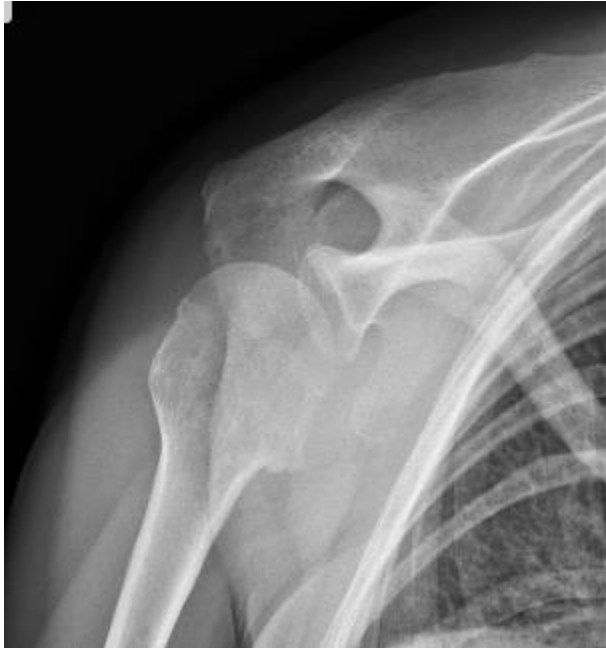FOCAL SPOT: Small or Large

IMAGING PLATE: 10x12 CR Cassette or DR detector

PATIENT POSITIOING: Have the patient standing (or sitting if can't stand) facing away from the table. Place the image receptor behind the patient under their shoulder. Then have patient lean back approximately 30-degrees toward the table (this allows for an axillary view of the shoulder).

CENTRAL RAY: Perpendicular to the image receptor centering on the glenohumeral joint.

IMAGE EVALUATION: The humeral head should be clearly visualized in its relationship with the glenoid. The humeral shaft will be foreshortened. The image will also be magnified but should still somewhat resemble a normal axial image.



WEST POINT AXILLARY SHOULDER

DISTANCE: 40"

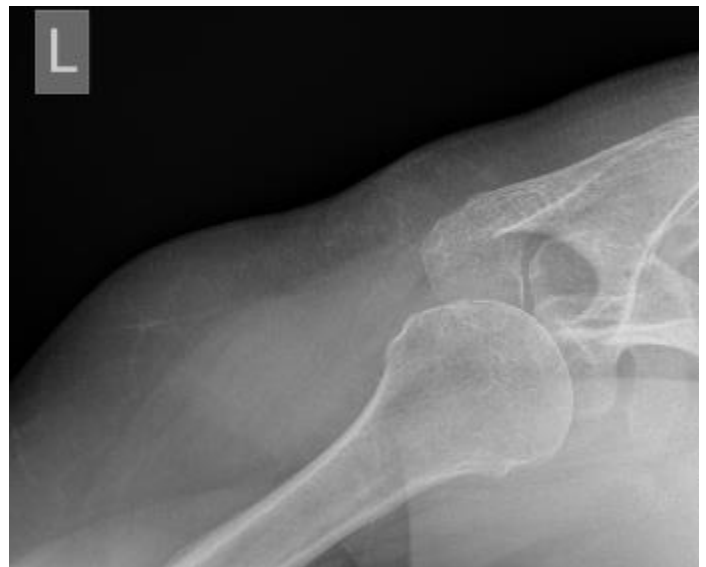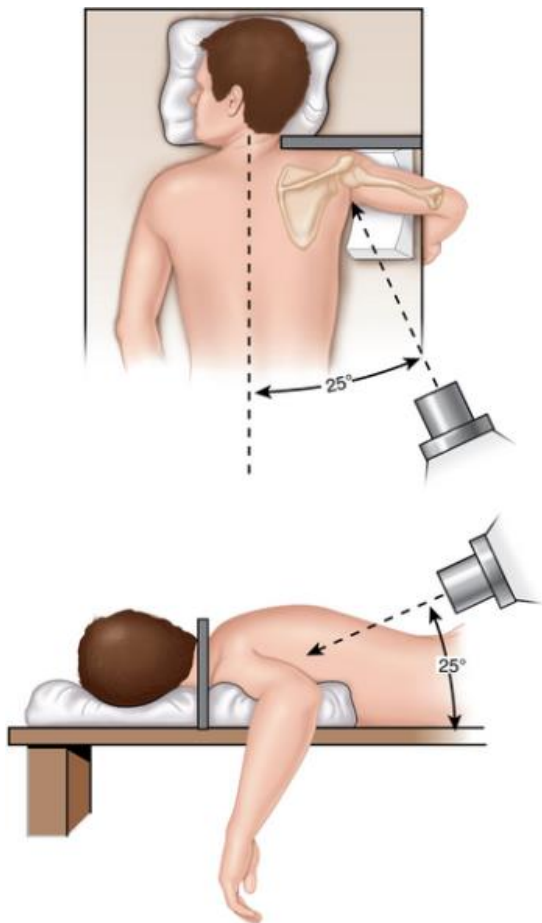
BUCKY: No

FOCAL SPOT: Small or Large

IMAGING PLATE: 10x12 CR Cassette or DR detector

PATIENT POSITIONING: Patient is in a prone position with shoulder placed on a sponge to elevate it off the table. Arm should then be abducted approximately 90-degrees with the forearm hanging over the edge of the table. The image receptor is placed superior to the shoulder (like a typical axillary view) and patient's head should be tilted toward the unaffected shoulder.

CENTRAL RAY: Central ray should be in a 25-degree caudal position and angled 25-degree toward the shoulder joint (See illustration below).



ZANCA (SHOULDER/ AC JOINTS)

DISTANCE: 40"

BUCKY: Yes

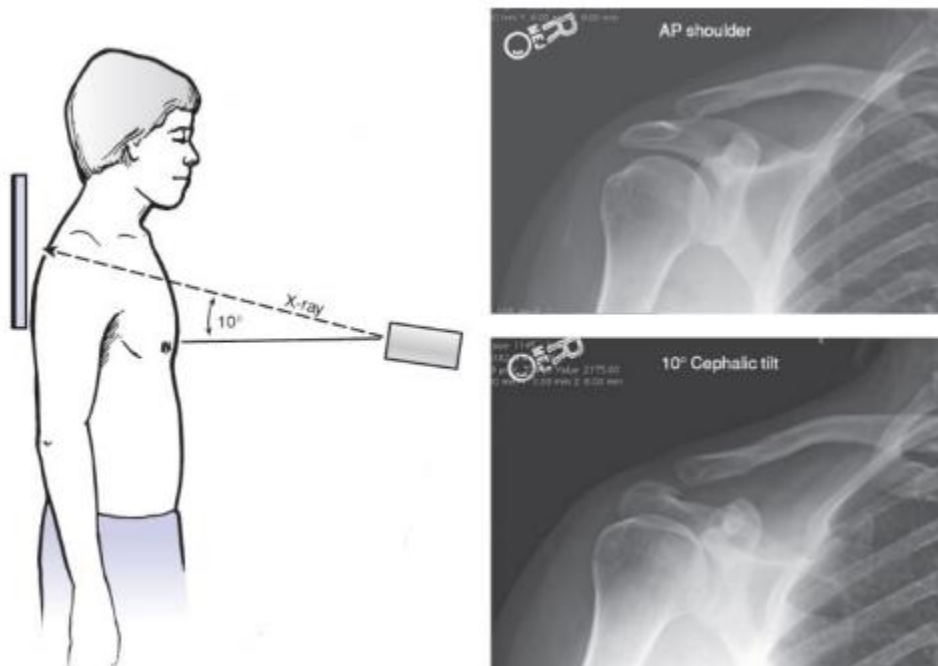
FOCAL SPOT: Small or Large

IMAGING PLATE: 10x12 CR Cassette or DR detector

PATIENT POSITIONING: Patient is placed in an AP position with arm in neutral position. The AC joint of interest should be in the center of the image receptor.

CENTRAL RAY: Centered at the AC joint with a 10-15-degree cephalic angle.

IMAGE EVALUATION: The AC joint should be free of superimposition.



BICIPITAL GROOVE (TANGENTIAL-INTERTUBERCULAR) SHOULDER

ROUTINES: can be performed via the Fisk method (erect) or supine.

DISTANCE: 40"

BUCKY: Yes

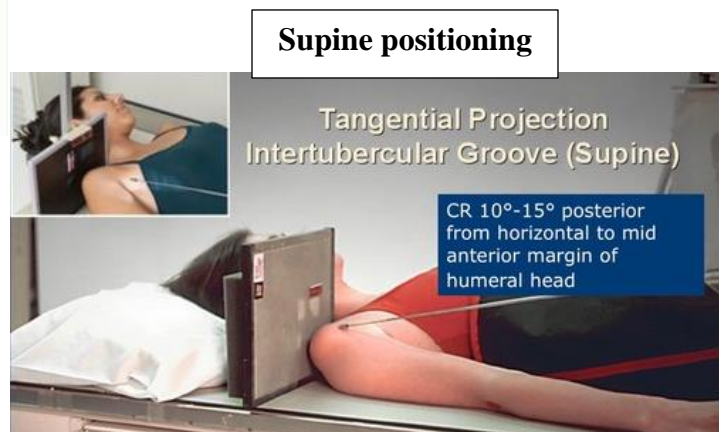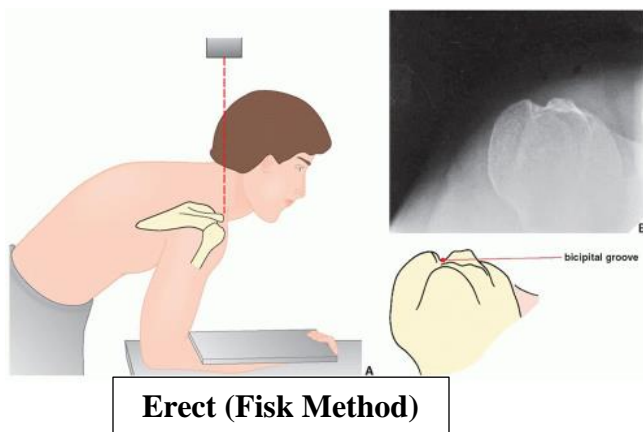
FOCAL SPOT: Small

IMAGING PLATE: 10x12 CR cassettes or DR detector

CENTRAL RAY: centered on humeral head but angle varies depending on position- see instructions below.

POSITIONING:

- **Erect (Fisk Method):** Have patient stand leaning over end of the table with elbow flex and posterior forearm on table. Hand will be supinated and holding the image receptor. Turn head away from affected side. With the patient leaning over slightly, place the humerus 10-15 degrees from vertical. CR is perpendicular to IR. If patient is unable to lean over cassette a 10-15 degree from vertical tube angle could be used directed at the patients hand.
- **Supine:** patient is supine with arm at side and hand supinated. The image receptor is placed against the top of the shoulder and side of neck (like an axillary shoulder). CR should be directed 10 to 15 degrees posterior from horizontal.



IMG1182L LEFT XR SCAPULA 2 VIEWS
IMG1182R RIGHT XR SCAPULA 2 VIEWS

SCAPULA

ROUTINES: AP, Lateral & Oblique.

DISTANCE: 40"

BUCKY: Yes

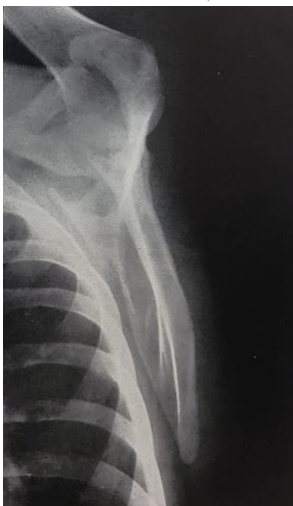FOCAL SPOT: Small

IMAGING PLATE: 10x12 CR cassettes or DR detector

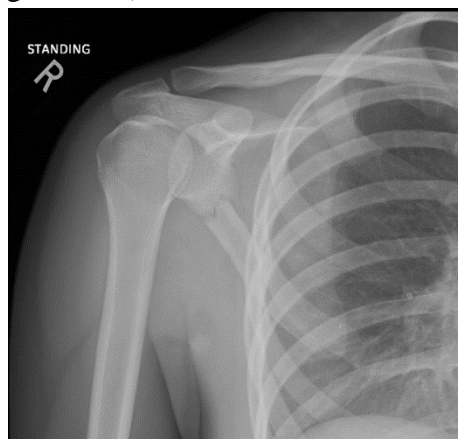
CENTRAL RAY: Perpendicular to the scapula.

HELPFUL POSITIONING:

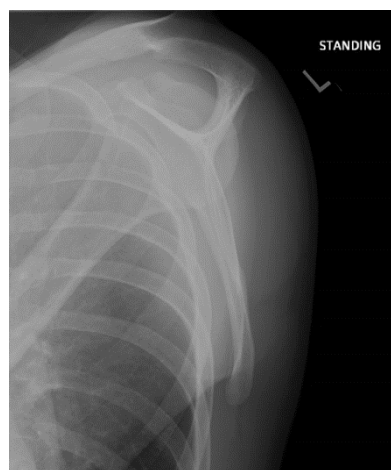
1. **AP:** Patient is supine or upright; arm is at the patient's side in the neutral position-similar to doing an AP of the Shoulder.
2. **Lateral:** Oblique injured side away from the bucky until scapula is in the lateral plane (approximately 45°). Place arm across forehead or across the body to rotate scapula away from the rib cage and to bring the humerus free of the scapula.
 - a. ***If taking follow up scapular fracture images it may be important to note where the fracture is.***
 - i. If body of the scapula is fractured: place arm out of the way like stated above.
 - ii. If looking at the acromion and coracoid process: the patient, if able, should be asked to flex arm at the elbow and place their hand behind their back.
3. **Oblique:** Extend the arm up & across the forehead. Turn the affected side away from the bucky about 15 degrees. Scapula should be free from superimposition of ribs. (See image below.)



Oblique



AP



Lateral

Updated 5/22/23 sla

IMG1166L LEFT XR HUMERUS 2+ VIEWS
IMG1166R RIGHT XR HUMERUS 2+ VIEWS

HUMERUS

ROUTINES: AP and Lateral diagonal on cassette to include both the shoulder & the elbow joint.

DISTANCE: 40"

BUCKY: Can be done non-bucky or standing at the upright bucky.

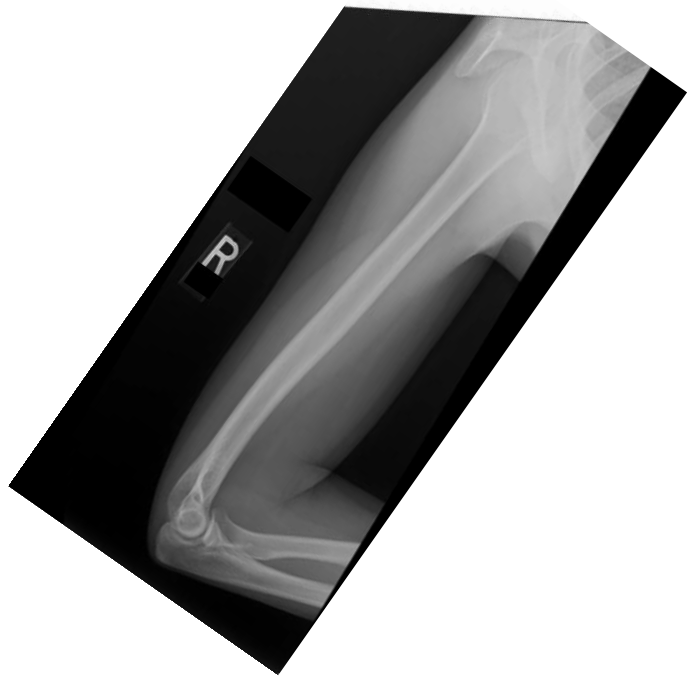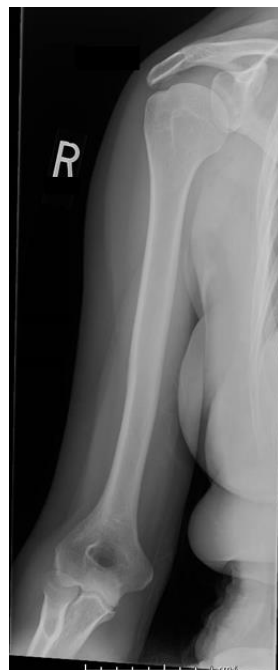
FOCAL SPOT: Small

IMAGING PLATE: CR-use 14 x17 cassette or DR detector

CENTRAL RAY: Perpendicular to the mid-shaft of the humerus.

HELPFUL POSITIONING:

1. If patient is unable to move arm for both views, a Transthoracic of the humerus must be taken.
2. If you cannot get a good lateral elbow; try doing the lateral with the patient in the PA position with the humerus up against the bucky.
3. If the patient has a hanging cast, the views should be done either sitting or standing.



IMG1145L LEFT XR ELBOW 2 VIEWS
IMG1145R RIGHT XR ELBOW 2 VIEWS
IMG1242L LEFT XR ELBOW 3 VIEWS TRAUMA
IMG1242R RIGHT XR ELBOW 3 VIEWS TRAUMA

ELBOW

ROUTINES: *PAIN/NO INJURY:* AP & Lateral.

TRAUMA: AP, Lateral & Radial Head view.

PEDIATRIC ROUTINE: No Radial Head on pts under 10 yrs. of age.

DISTANCE: 40"

BUCKY: No

FOCAL SPOT: Small

IMAGING PLATE: CR cassette-8x10 or DR detector

CENTRAL RAY: *AP & Lateral:* Perpendicular to elbow joint.

Radial Head: 45° tube angle up the humerus @ radial head.

HELPFUL POSITIONING:

1. *Lateral:* Have patient's entire arm all on the same plane. Bend elbow 90°.
2. *Radial head:* place elbow in lateral position & angle 45° up the humerus to throw the radial head free of the ulna.
3. If patient is not able to extend arm completely, separate views must be taken of the distal humerus & proximal forearm. If necessary, angle accordingly.

ELBOW-STRESS VIEW

ROUTINES: Elbow Stress View.

DISTANCE: 40"

BUCKY: No

FOCAL SPOT: Small

IMAGING PLATE: 8x10 CR cassette or DR detector

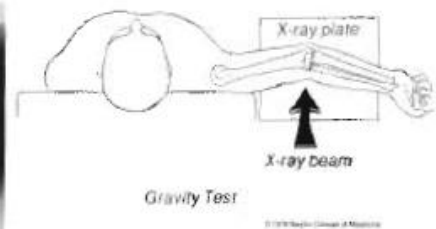
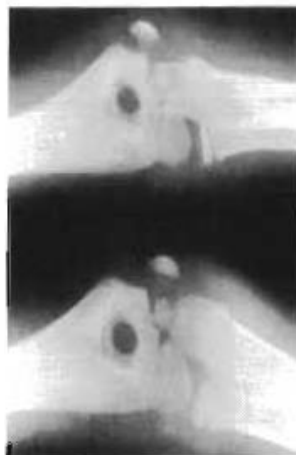CENTRAL RAY: Perpendicular to elbow joint.

HELPFUL POSITIONING:

1. Patient lying on table with arm abducted away from body.
2. Hand externally rotated to bring elbow to AP position.
3. Use small table or cart to hold image receptor in place.

Neutral x-table elbow

Stress view x-table elbow



IMG1154L LEFT XR FOREARM 2 VIEWS
IMG1154R RIGHT XR FOREARM 2 VIEWS

FOREARM

ROUTINES: AP & Lateral to include both the elbow & the wrist joints.

DISTANCE: 40"

BUCKY: No

FOCAL SPOT: Small

IMAGING PLATE: 10x12 CR cassette (may be done diagonally for longer forearms) or DR detector.

CENTRAL RAY: Perpendicular to mid-forearm.

HELPFUL POSITIONING:

Lateral: Have patient's entire arm all on the same plane. Bend elbow 90° - turn thumb up as much as possible. If unable to get a good lateral of the wrist on the lateral forearm, do a separate lateral wrist.

IMG1202L LEFT XR WRIST 3-5 VIEWS
IMG1202R RIGHT XR WRIST 3-5 VIEWS

WRIST

ROUTINES: PA, Oblique & Lateral.

DISTANCE: 40"

BUCKY: No

FOCAL SPOT: Small

IMAGING PLATE: 8x10 CR cassette or DR detector

CENTRAL RAY: Perpendicular to carpal bones.

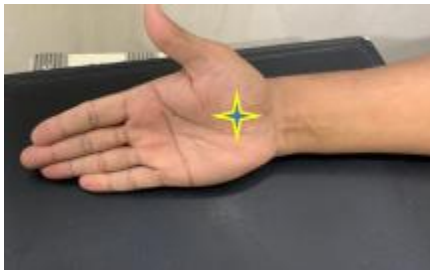SEE ALSO/OTHER VIEWS:

1. **Gripping view**-done AP squeezing a roll of gauze
2. **Supinated wrist- hook/pisiform view**- place palm in 60-degree supination. Keep the x-ray beam perpendicular to image receptor.

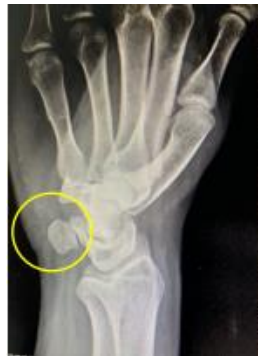[Go to "Carpal Tunnel"](#)

[Go to "Gipping/Fist View"](#)

[Go to "Navicular View"](#)



Supinated wrist/hook/pisiform view position and exam.



WRIST-CARPAL TUNNEL

ROUTINES: Carpal Tunnel view (Gaynor-Hart).

DISTANCE: 40"

BUCKY: No

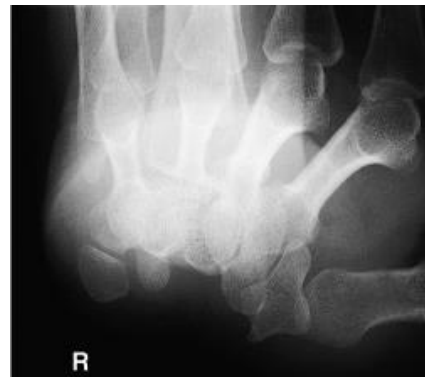FOCAL SPOT: Small

IMAGING PLATE: 8x10 CR cassette or DR detector.

CENTRAL RAY: 25-30° angle to the long axis of the hand approximately 1" distal to the base of the metacarpal.

HELPFUL POSITIONING:

1. Hand placed prone on the table with hand and entire arm in a line.
2. Hyperextend wrist by grasping fingers and pulling back. Increase tube angle if patient is unable to hyperextend wrist very far.



WRIST-NAVICULAR VIEWS

ROUTINES: AP, PA Ulnar Flexion views to be done along with routine wrist series (a total of 5 views) for a complete navicular series.

DISTANCE: 40"

BUCKY: No

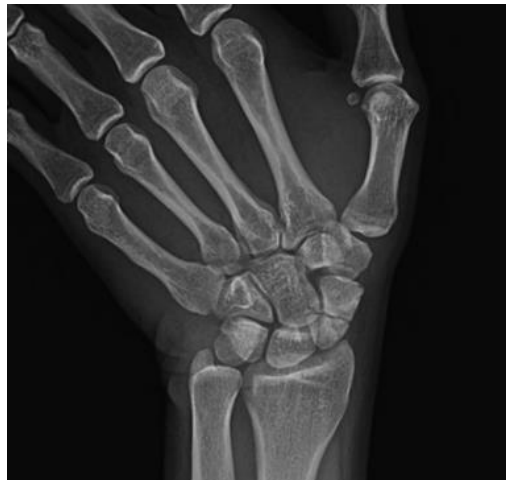FOCAL SPOT: Small

IMAGING PLATE: 8x10 CR cassettes or DR detector

CENTRAL RAY:

AP: Perpendicular to scaphoid bone.

PA Ulnar Flexion: 15-20° proximally toward the elbow centered on the scaphoid. See image below.



PA Ulnar Flexion

WRIST-FIST OR GRIPPING VIEWS

ROUTINES:

FIST VIEW: PA wrist views done with a closed fist as specified by ordering doctor.

GRIPPING VIEW: AP wrist view done gripping a roll of gauze.

DISTANCE: 40"

BUCKY: No

FOCAL SPOT: Small

IMAGING PLATE: 8x10 CR cassettes or DR detector.

CENTRAL RAY: Perpendicular to carpal bones.

HELPFUL POSITIONING:

When the patient is making a fist or holding the gauze roll, make sure they do not lift their hand off the image receptor or oblique their wrist.

IMG1158L LEFT XR HAND 3+ VIEWS
IMG1158R RIGHT XR HAND 3+ VIEWS

HAND

ROUTINES: PA, Oblique & Lateral.

DISTANCE: 40"

BUCKY: No

FOCAL SPOT: Small

IMAGING PLATE: 8x10 CR cassette or DR detector

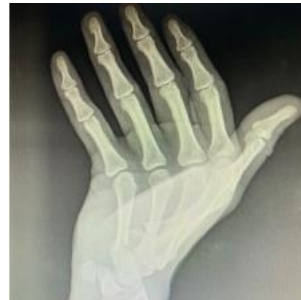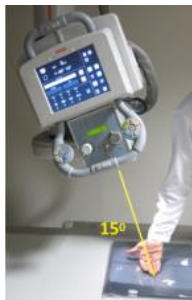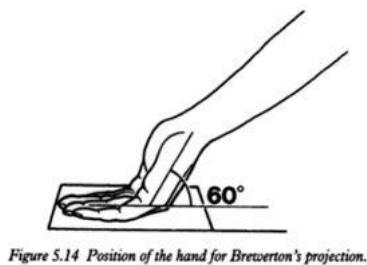CENTRAL RAY: Perpendicular to 3rd MP joint.

ADDITIONAL COMMENTS:

1. **ARTHRITIS:** Each hand done PA on separate image receptors to include wrists. ***Run under ARTHRITIC HAND on CR menu.***
2. **LATERAL:** Fan out fingers.

SEE ALSO/OTHER VIEWS:

Brewerton view-AP Hand with wrist lifted off table so fingers are flat; palm should be lifted 45-60°. Central ray angled 15° laterally toward the 5th digit, throwing the 5th digit away from the hand.



Positioning and example of a Brewerton hand view.

HAND-Bone Age

ROUTINES: PA LEFT Hand (to include Wrist)

DISTANCE: 40"

BUCKY: No

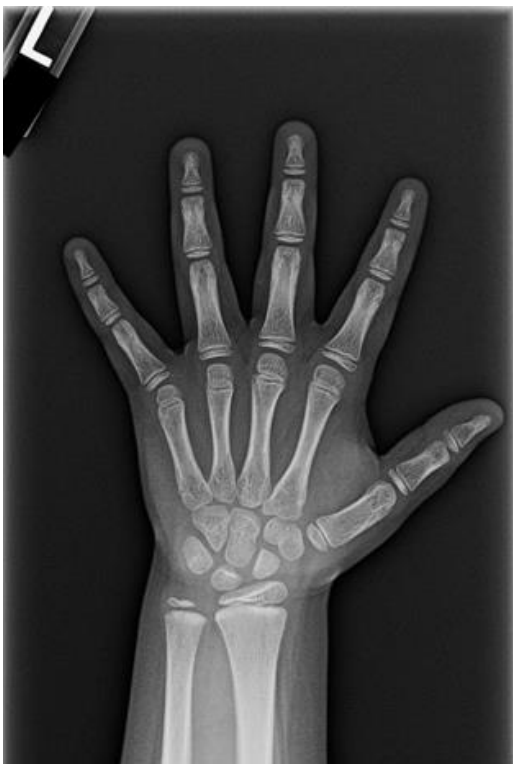FOCAL SPOT: Small

IMAGING PLATE: 8x10 CR cassette or DR detector

CENTRAL RAY: Perpendicular the 3rd MP joint.

ADDITIONAL COMMENTS:

1. Hand and fingers must be flat with no rotation so that joint spaces are open.
2. Run under **ARTHRITIC HAND on CR menu.**



If the child is under 2yrs, do the PA left hand to include wrist first. If you see the development of 2 bones in the wrist, you are done. If not, do an AP view of the left clavicle to wrist on one cassette & an external oblique of the left mid-femur to the big toe.

IMG1153L LEFT XR FINGERS
IMG1153R RIGHT XR FINGERS

FINGER

ROUTINE: PA, Oblique & Lateral of affected finger to include carpal bones.

DISTANCE: 40"

BUCKY: No

FOCAL SPOT: Small

IMAGING PLATE: CR – perform each view individually on an 8x10 cassette or DR detector.

CENTRAL RAY: Perpendicular to MP joint.

ADDITIONAL COMMENTS:

1. Indicate digit of interest on the image.
2. The Index Finger is done with the finger placed closest to the cassette. (The finger is turned so the lateral side is down).

IMG1153L LEFT XR FINGERS
IMG 1153R RIGHT XR FINGERS

THUMB

ROUTINE: AP, Oblique & Lateral to include carpal bones.

DISTANCE: 40"

BUCKY: NO

FOCAL SPOT: Small

IMAGING PLATE: CR-- perform each view individually on an 8x10 cassettes or DR detector.

CENTRAL RAY: Perpendicular to the MP Joint

ADDITIONAL COMMENTS:

Indicate digit of interest on the image.

SEE ALSO/OTHER VIEWS:

[Go to "Roberts View"](#)

IMG1153L LEFT XR FINGERS
IMG1153R RIGHT XR FINGERS

THUMB-ROBERTS VIEW

ROUTINE: AP thumb with hand rotated out more to see MCP Joint, arm should be outstretched and all on one plane.

DISTANCE: 40"

BUCKY: No

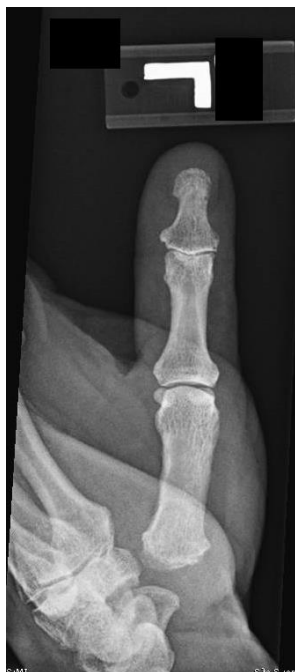FOCAL SPOT: Small

IMAGING PLATE: 8x10 CR cassette or DR detector

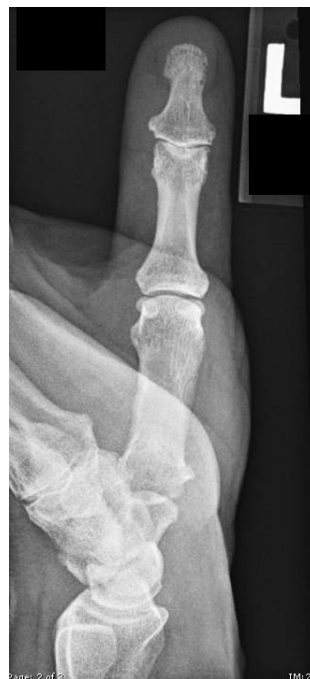CENTRAL RAY: Perpendicular to MCP joint.

ADDITIONAL COMMENTS:

Indicate digit of interest on the image.



Robert's view- notice the MCP joint area is free of superimposition vs the normal AP/PA view.



AP/PA

IMG1153L LEFT XR FINGERS
IMG1153R RIGHT XR FINGERS

THUMB-STRESS VIEW

ROUTINE: PA of both thumbs with stress on one image.

DISTANCE: 40"

BUCKY: No

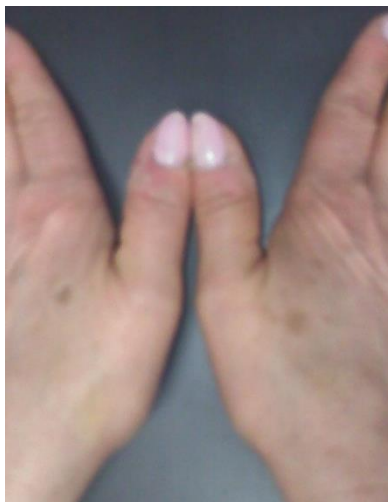FOCAL SPOT: Small

IMAGING PLATE: Both thumbs on an 8x10 CR cassette or DR detector

CENTRAL RAY: Perpendicular to MCP joints of both thumbs.

HELPFUL HINTS:

1. Have patient touch tips of thumbs together and push against each other.
2. Do not allow patient to drop ends of thumbs. Keep them parallel to the image receptor.



IMG1175L LEFT XR LOWER EXTREMITY INFANT 2 VIEWS
IMG1175R RIGHT XR LOWER EXTREMITY INFANT 2 VIEWS

INFANT LOWER EXTREMITY

ROUTINE: AP and Lateral view of lower extremity including hip joint to ankle joint.

One single image is taken for each view.

DISTANCE: 40"

BUCKY: NO

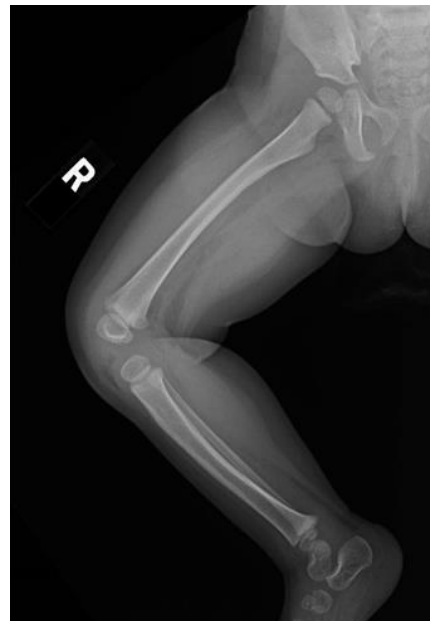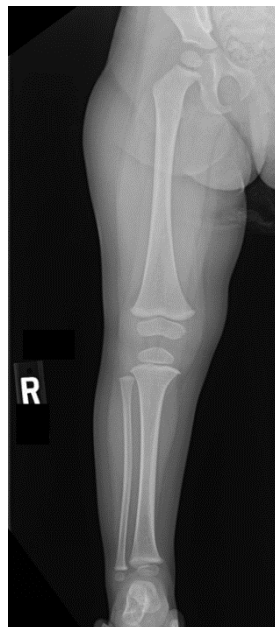
FOCAL SPOT: Small

IMAGING PLATE: Appropriately sized CR Cassette or DR detector

CENTRAL RAY: Perpendicular to the image receptor centered at the knee joint.

ADDITIONAL COMMENTS:

1. Ordered for when child is *under 1 year old* to include entire lower extremity on 1 image.
2. Lateral image is done in a frog lateral position.



IMG1237 XR BONE LENGTH/SCANOGRAM/HIP TO ANKLE

HIP TO ANKLE/LEG LENGTH

ROUTINE: AP of entire lower extremity from hip to ankle.

***Hip to Ankle/Leg Length exams should only be done at sites that have a long leg CR cassette or that can stitch DR images.**

DISTANCE: 96"

BUCKY: No

FOCAL SPOT: Large

IMAGING PLATE: Long femoral CR cassette with grid

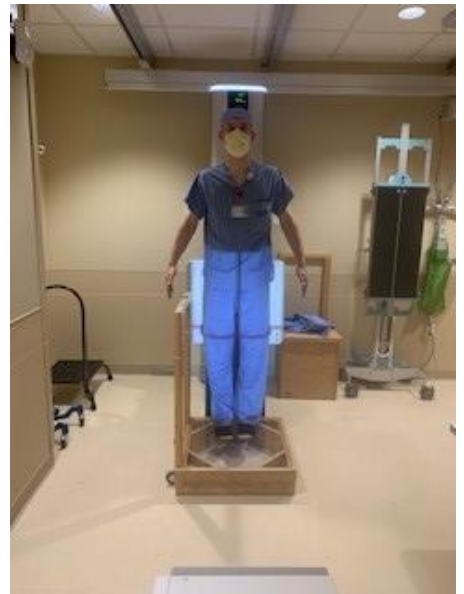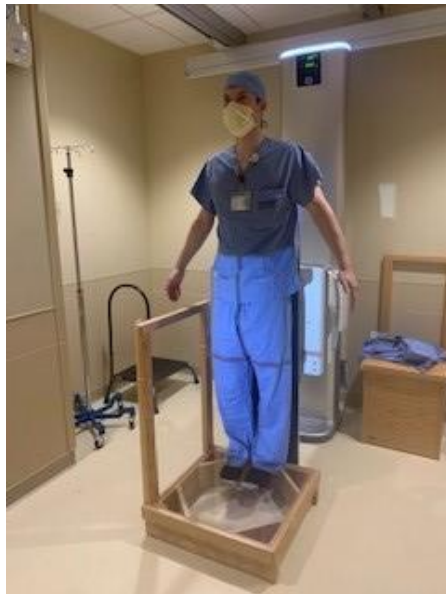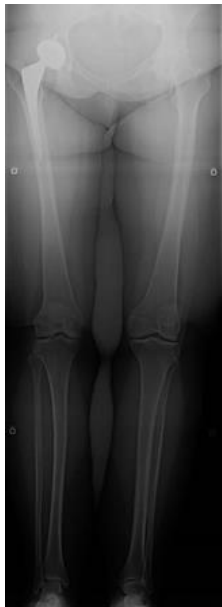CENTRAL RAY: Perpendicular to the image receptor.

HELPFUL POSITIONING:

1. Have patient stand on hindfoot alignment board with image receptor edge on floor in front of wall stand.
2. Position patient so patellae are facing forward.
3. Measure through the lumbar spine area.

ADDITIONAL COMMENTS:

If the patient has a large belly, have them pull up to flatten their belly. Make sure to have their hands out of the way of the hips.



FALSE PROFILE HIP TO ANKLE

ROUTINE: Lateral of entire lower extremity from hip to ankle. Usually of just one side. If both sides of lower extremities need to be performed they may have to be performed separately.

***Hip to Ankle/Leg Length exams should only be done at sites that have a long leg CR cassette or that can stitch DR images.**

DISTANCE: 96"

BUCKY: No

FOCAL SPOT: Large

IMAGING PLATE: Long femoral CR cassette with grid or scoli film if patient is small enough

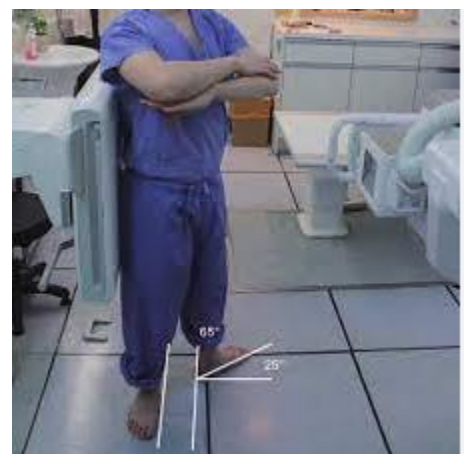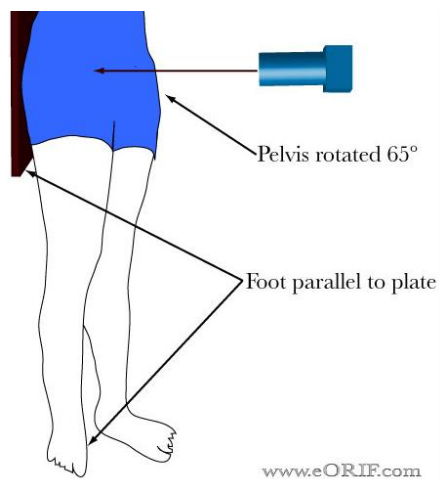
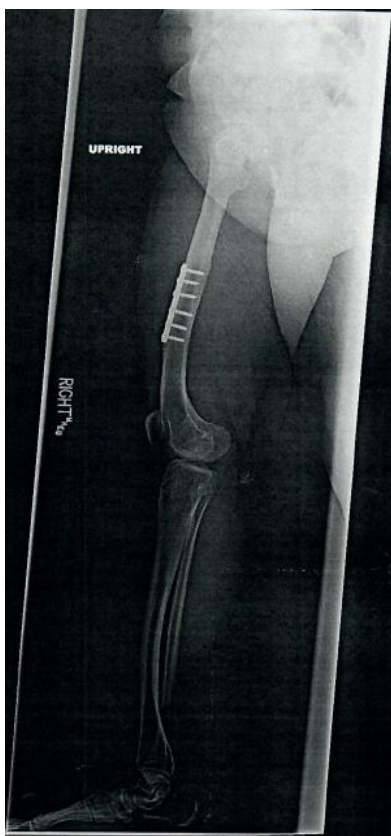CENTRAL RAY: Perpendicular to the image receptor.

HELPFUL POSITIONING:

1. Have patient stand on hindfoot alignment board (or other stool/pedestal) with image receptor edge on floor in front of wall stand.
2. Position patient so foot and knee are in a lateral position. Hip will be in a frog like position. Position as you would for a hip view in the false profile position (see below).
- 3.
4. Try to straighten knee/leg as much as possible- may be hyperextended.
5. Measure through the lumbar spine area.

ADDITIONAL COMMENTS:

If the patient has a large belly, have them pull up to flatten their belly. Make sure to have their hands out of the way of the hips.



IMG1237 XR BONE LENGTH/SCANOGRAM/HIP TO ANKLE

SCANOGRAM

ROUTINE: AP coned down view of hips, knees, and ankles together on one IR.

DISTANCE: 40"

BUCKY: Yes or Stationary Grid

FOCAL SPOT: Large

IMAGING PLATE:

La Crosse: Use Long Leg CR cassette tabletop with stationary grid

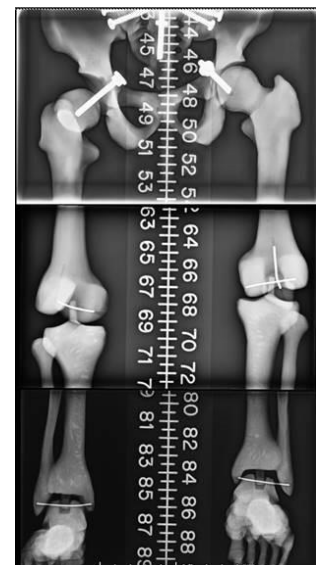
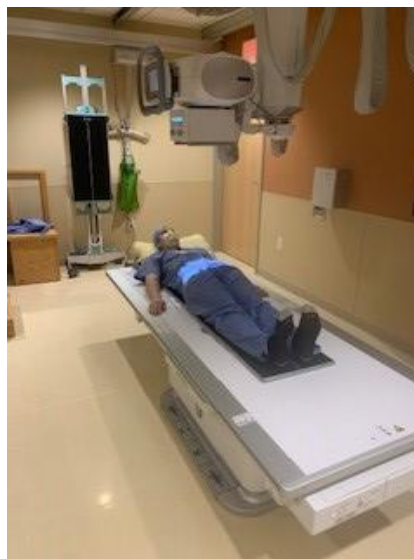Konica sites: Use DR detector in table bucky

CENTRAL RAY: Perpendicular to the hip, knee, and ankle joints

HELPFUL POSITIONING:

1. Place an ortho ruler on top of table and tape it down securely. If using long leg CR cassette, tape ruler to front of grid.
2. Lay patient on top of the ruler. Make sure knees are pointed forward. If necessary, tape feet together.
3. Instruct patient to remain still throughout the 3 separate exposures.
4. Take 3 exposures, collimating down to hips, then knees, then ankles. Move tube longitudinally ONLY; do not move transversely.
5. Stitch images.

ADDITIONAL COMMENTS: If using long leg CR cassette, run under Whole Leg Stitch. Adjust masking, stitch images, then reprocess as Scanogram.



IMG1116 XR SACRUM AND COCCYX

SACRUM/COCCYX

ROUTINE: AP of both the Sacrum & the Coccyx separately & Lateral of both on one.

DISTANCE: 40"

BUCKY: YES

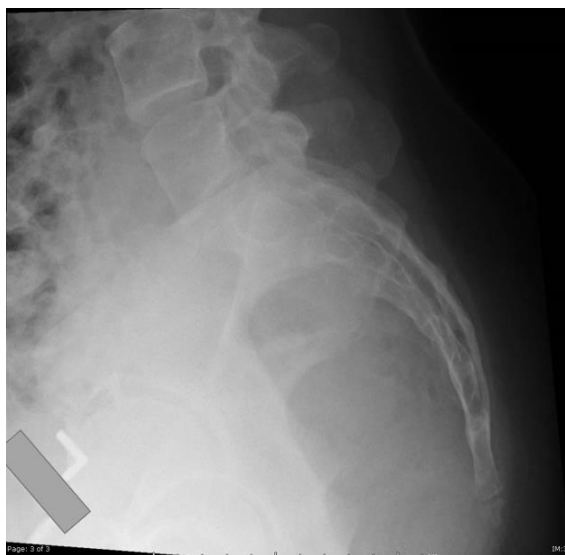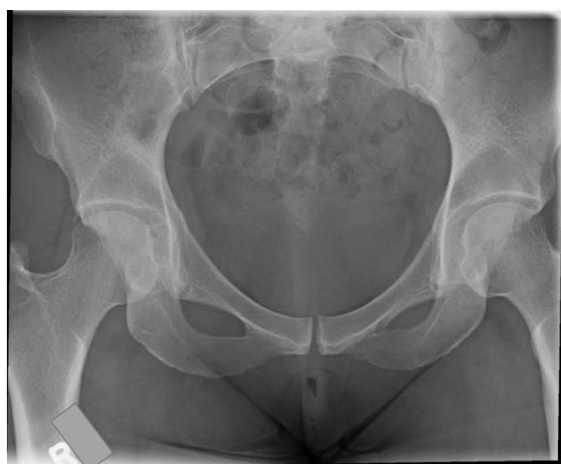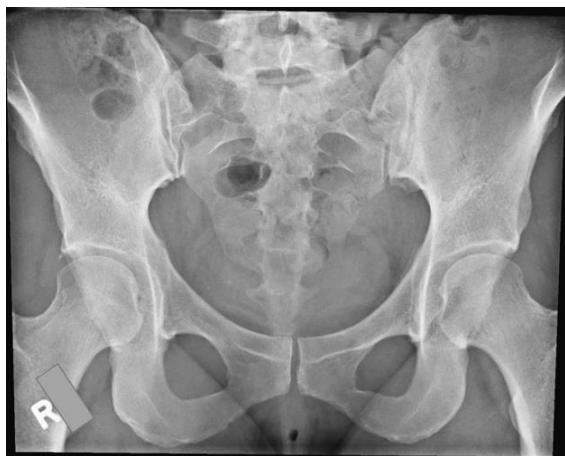FOCAL SPOT: Large

IMAGING PLATE: 10x12 CR cassettes or DR detector

CENTRAL RAY:

Sacrum: 15° cephalic angle entering at the midline halfway between the pubic symphysis and the ASIS.

Coccyx: 10° caudal angle entering 2" superior to the pubic symphysis.



Reviewed 10/01/19

IMG1115 XR SI JOINTS 3 VIEWS

SACROILIAC JOINTS

ROUTINE: 1 AP of both joints on one film and an oblique of each joint (3 images in total).

DISTANCE: 40"

BUCKY: YES

FOCAL SPOT: Large

IMAGING PLATE: 10x12 CR cassettes or DR detector

CENTRAL RAY:

AP: Perpendicular to the image receptor entering at the midline at the level of ASIS.

Obliques: Perpendicular to the image receptor entering at the elevated SI joint.

HELPFUL POSITIONING:

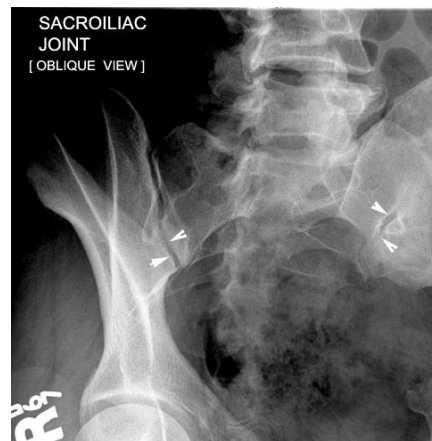
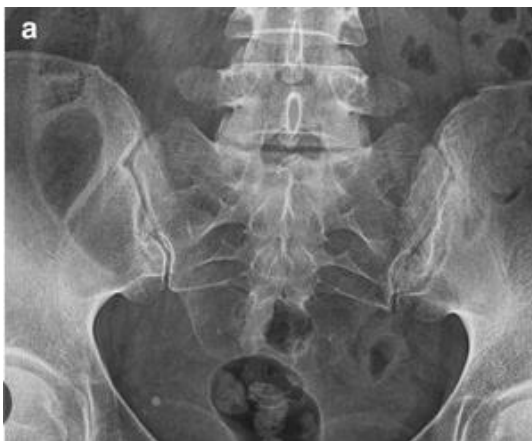Obliques: Done AP. Roll patient up about 30° - mark the side that is up.

ADDITIONAL COMMENTS:

Ferguson Views:

AP: Knees flexed as much as possible. Cephalic tube angle entering at the level of the ASIS.

PA: 15° caudal angle exiting the level of the ASIS.



IMG1200 PELVIS FOR PAIN OR TRAUMA (Adult)
IMG1205 PELVIS AND LATERAL HIP
IMG1162L 2V LEFT HIP
IMG1162R 2V RIGHT HIP
IMG1107 PELVIS & BOTH LATERAL HIPs
IMG1265 PELVIS FOR INFANT & CHILD (CHILD UNDER 12)
IMG1265 PELVIS & FROGLEG PELVIS FOR INFANT & CHILD (CHILD UNDER 12)

PELVIS

ROUTINE: AP Pelvis.

DISTANCE: 44"

BUCKY: Yes

FOCAL SPOT: Large

IMAGING PLATE: 14x17 CR cassette or DR detector

CENTRAL RAY: Perpendicular entering the midline 2" superior to the pubic symphysis.

HELPFUL POSITIONING: Patient is supine with legs extended & internally rotated 15°.

ADDITIONAL COMMENTS:

1. *Pelvis for Hips*-center lower-top of image receptor at ASIS. Be sure to include all the prosthesis. IMG1200
2. *Pelvis for Sacroiliitis*-do a PA pelvis. (IMG1200)

SEE ALSO/OTHER VIEWS:

Ferguson view of Pelvis-30° cephalic tube angle done to demonstrate L4-L5 & SI joints.

PELVIS-INLET/OUTLET VIEWS

ROUTINE: Inlet and Outlet views of Pelvis.

DISTANCE: 44"

BUCKY: Yes

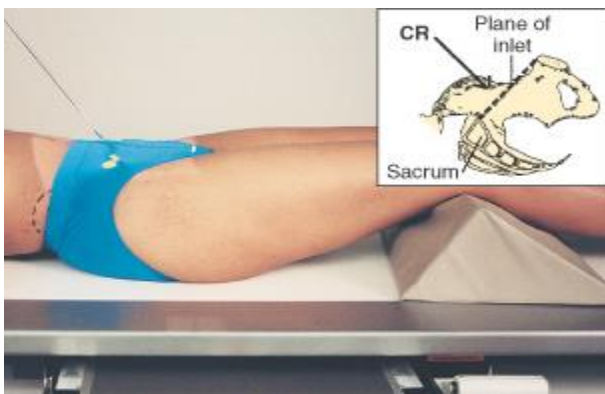
FOCAL SPOT: Large

IMAGING PLATE: 14x17 CR cassette or DR detector

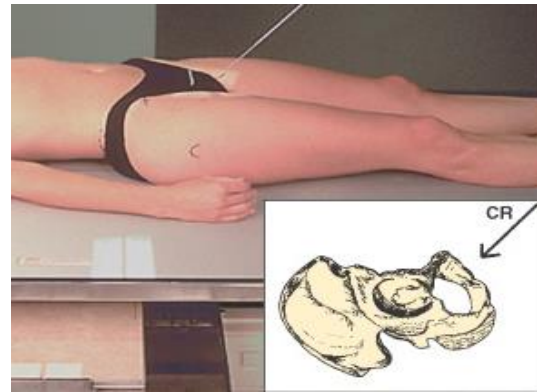
CENTRAL RAY:

1. **Inlet**-35° **caudal** angle entering at midline at the level of the ASIS.
2. **Outlet**-35° **cephalic** angle entering at midline at the symphysis.

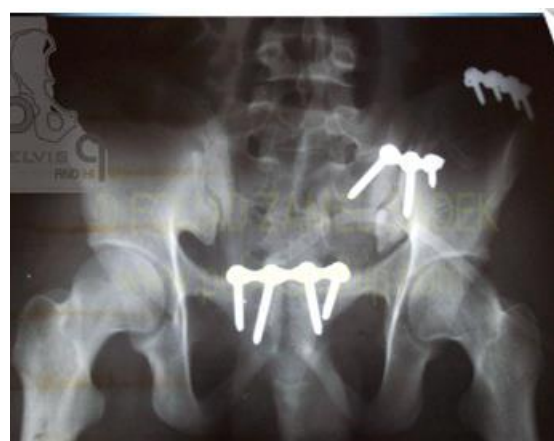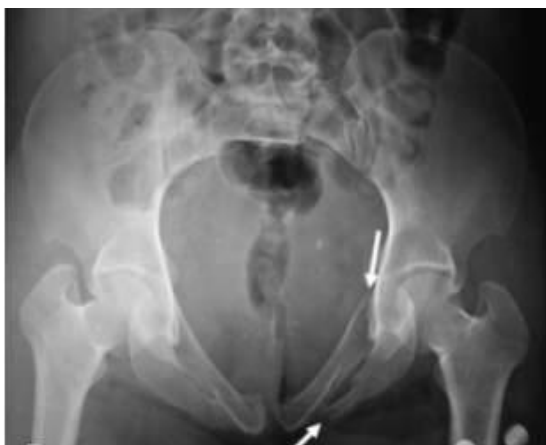***At least one of these views should include the crests. ***



Inlet View



Outlet View



PELVIS-JUDET VIEWS

ROUTINE: 45° Obliques of the Pelvis.

DISTANCE: 44"

BUCKY: Yes

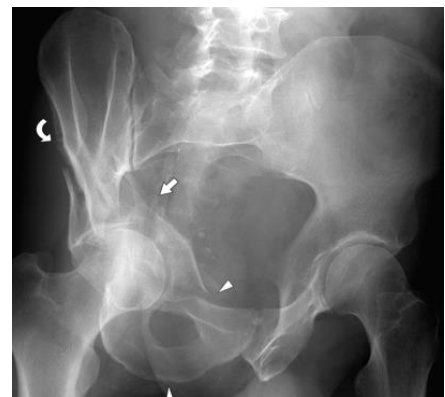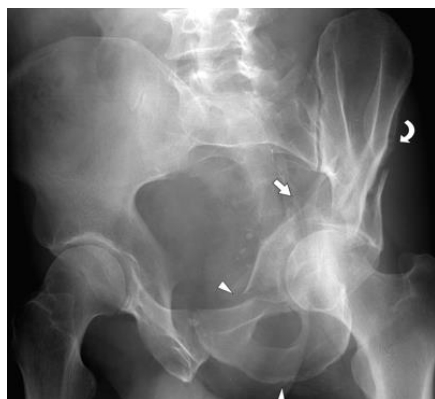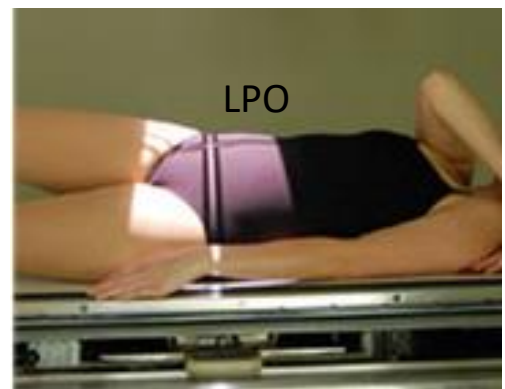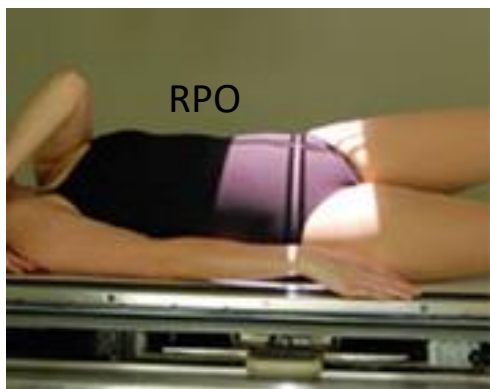
FOCAL SPOT: Large

IMAGING PLATE: 14x17 CR cassette or DR detector

CENTRAL RAY: Mid pelvis – perpendicular to image receptor.

HELPFUL POSITIONING: Patient supine, oblique patient 45° both ways (RPO & LPO).

ADDITIONAL COMMENTS: Judet views of a single hip may be ordered if doctor desires.



IMG1162L LEFT XR HIP 2 VIEWS
IMG1162R RIGHT XR HIP 2 VIEWS
IMG1205 XR PELVIS AND LATERAL HIP
IMG1107 XR PELVIS AND BILATERAL HIPS
IMG1265 PELVIS & FROGLEG FOR INFANT/CHILD

HIP

ROUTINE: TRAUMA/INJURY: AP Pelvis and X-table Lateral of affected side(s).

PAIN – NO INJURY:

Age 18+ - Standing Low AP Pelvis and X-table Lateral of affected side(s).

Age 40+ - Use TRAUMACAD template on AP view if available.

Age 14-18 years – AP and Lateral Hip.

< Age 14 - AP Pelvis and Frog Leg Pelvis.

DISTANCE: 40”

BUCKY: Yes

FOCAL SPOT: Large

IMAGING PLATE: 10x12 or 14x17 CR Cassette or DR detector

CENTRAL RAY: Perpendicular to femoral neck.

HELPFUL POSITIONING:

Standing Low AP Pelvis: Put top of image receptor at level of ASIS.

ADDITIONAL COMMENTS:

1. **Post-Op:** You must include all the surgical hardware and glue on both views.
2. X-Table Lateral is preferred, but if you are unable to view the femoral head on a X-Table Lateral due to patient size or have equipment limitations, you may do a Frog Leg Lateral.

FALSE PROFILE HIP

DISTANCE: 40"

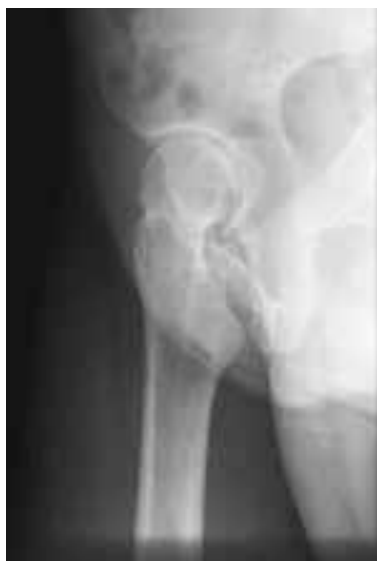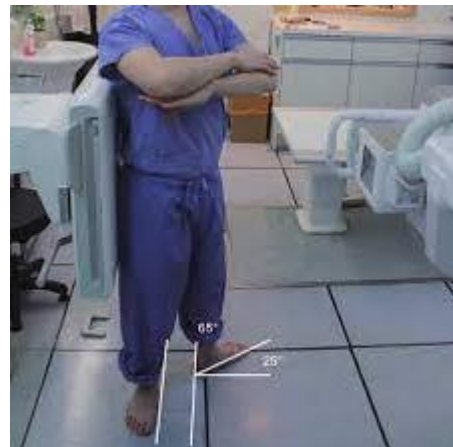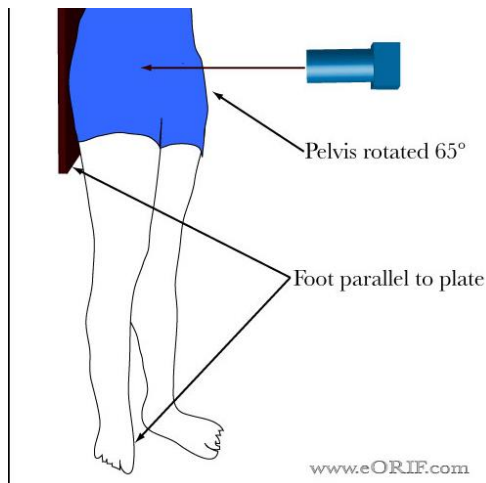
BUCKY: Yes, routinely performed at upright bucky.

FOCAL SPOT: Large

IMAGING PLATE: 10x12 or 14x17 CR Cassette or DR detector

CENTRAL RAY: Perpendicular entering at level of the hip joint.

POSITIONING: Patient is standing laterally with the hip of interest against the image receptor. The unaffected hip should be rotated back just far enough to be out of the way of the hip of interest as to get the best lateral hip as possible. *If bilateral hips are ordered, they need to be performed on separate images.*



DUNN HIP/PELVIS

DISTANCE: 40"

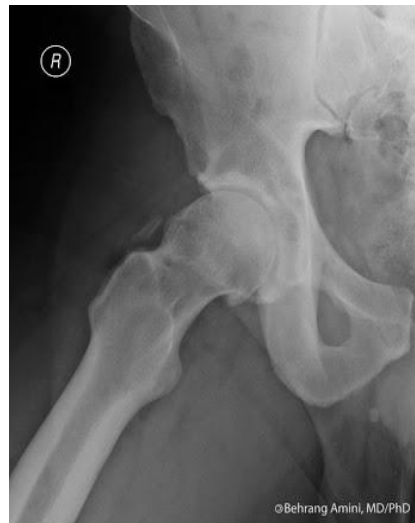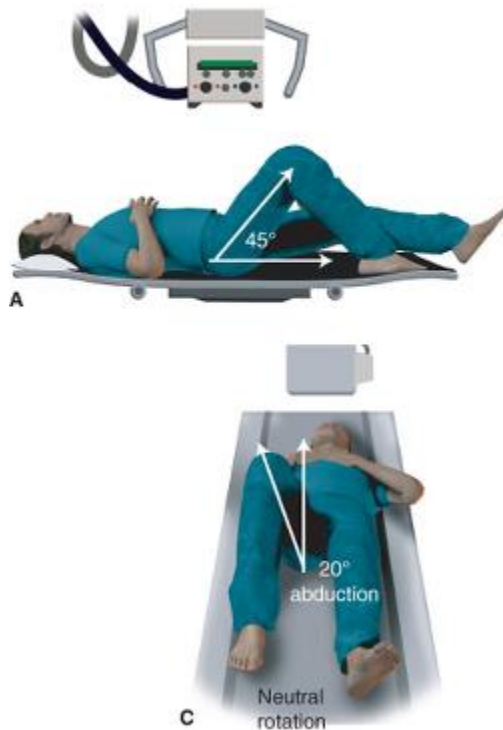
BUCKY: Yes

FOCAL SPOT: Large

IMAGING PLATE: 10x12 or 14x17 CR Cassette or DR detector

CENTRAL RAY: Perpendicular entering at level of the hip joint.

POSITIONING: Patient is supine with the pelvis in neutral rotation (ASIS equidistant from tabletop for pelvis). The hip joint is flexed 45° and abducted 20° while the pelvis remains in neutral rotation. *If bilateral hips are ordered, they can be performed on the same image (unless specified differently from ordering provider).*



PELVIS INSTABILITY SERIES (Flamingo Views)

ROUTINE: Standing AP Pelvis with Bilateral Flamingo Views for a total of 3 images.

DISTANCE: 40"

BUCKY: Yes, Upright Bucky

FOCAL SPOT: Large

IMAGING PLATE: DR-16x16 Detector or 14x17 CR cassette

CENTRAL RAY: Perpendicular entering the midline 2" superior to the pubic symphysis.

HELPFUL POSITIONING:

1. Standing AP Pelvis done with patient standing evenly on both feet and without rotation. No shielding.
2. Flamingo views are done sequentially—First, have the patient bring their feet together. Then transfer weight to the right leg and lift left foot barely off the floor (toe touch position). Then, repeat for the opposite side. No rotation of pelvis. Patient to hold on to something for stability only if needed.

2 VIEW PELVIS (with and w/o CORI)

(DR. LEHMAN AND DR. WHALEN)

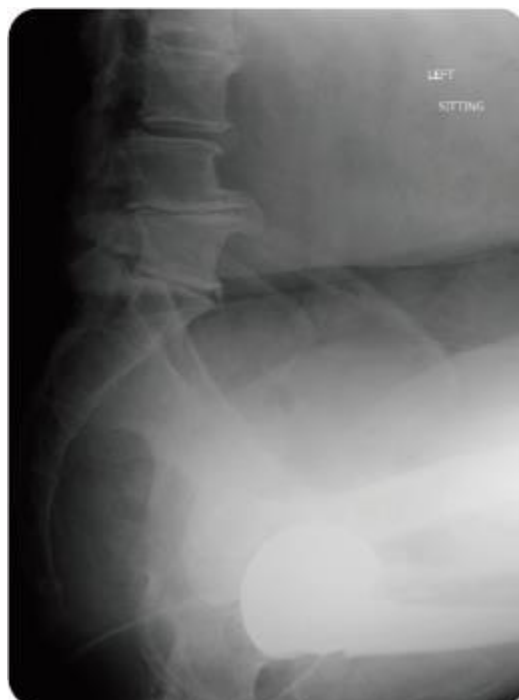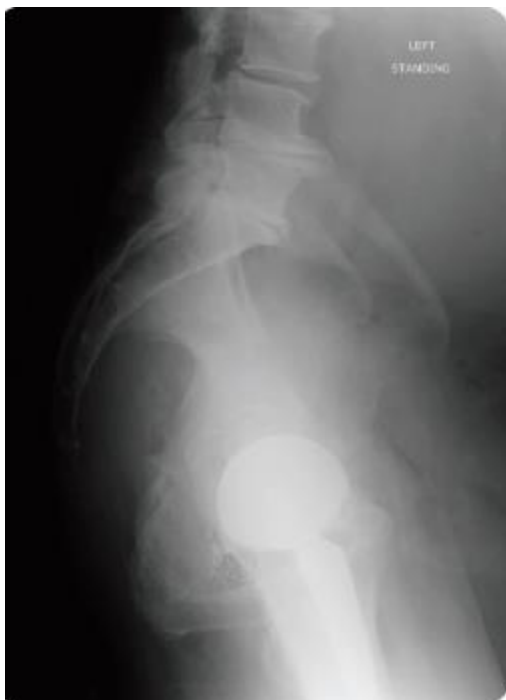- Standing Lateral Pelvis

- Pt standing naturally (left lateral)
- Arms positioned above area of interest (holding onto something or arms crossed resting on shoulders). Arms should not be raised above shoulders/head.
- Center at the center of the pelvis. This will include L3 down to symphysis pubis, including 1/3 of proximal femur (if able).
- Need to visualize
 - L3, ASIS, Top of sacrum/S1 endplate & hips

- Sitting Lateral Pelvis

- please ensure femurs/thighs are parallel to the floor-90-degree bend
- Pt sitting on box (brown box in ortho)/chair (may need to place a sponge or board on chair if patient sinks into chair).
- Center at the center of the pelvis. This will include L3 down to symphysis pubis, including 1/3 of proximal femur (if able).
- Need to visualize
 - L3, ASIS, Top of sacrum/S1 endplate & hips

***CORI is a computer software to help aide the physician in hip surgeries, optimal contrast and density are needed to get a clear view of the S1 endplate, the ASIS, and the pubic symphysis. * This exam can also be ordered if it doesn't specify its for CORI software-abide by same positioning and technique guidelines.**



Updated 5/22/23 sla

IMG1151L LEFT XR FEMUR 2 VIEWS
IMG1151R RIGHT XR FEMUR 2 VIEWS

FEMUR

ROUTINE: AP and Lateral Hip down **AND** AP & Lat Knee up to obtain overlap (four images).

DISTANCE: 40"

BUCKY: Yes

FOCAL SPOT: Large

IMAGING PLATE: CR-14x17 Cassette, 10x12 Cassette for Cross-table Lateral Hip or DR
detector

CENTRAL RAY: Perpendicular to mid-shaft of the femur.

HELPFUL POSITIONING:

AP: Do first AP from hip down and second AP from knee up.

Lateral: Do Lateral from knee up and x-table Lateral of affected hip.

ADDITIONAL COMMENTS:

1. Cross Table Lateral may be used on knee up if patient is unable to roll.
2. Measure mid-femur to get a good technique for knee up view.

IMG1168L LEFT XR KNEE 1-2 VIEWS
IMG1168R RIGHT XR KNEE 1-2 VIEWS
IMG1171L LEFT XR KNEE 3 VIEW
IMG1171R RIGHT XR KNEE 3 VIEW
IMG1289 XR KNEE BILATERAL (MULTIPLE VIEWS)

KNEE

ROUTINE: TRAUMA/INJURY: AP on the table & X-table Lateral.

PAIN – NO INJURY:

Age 18+ - Bilateral Standing AP, Bilateral PA Flexion, Bilateral Sunrise, Lateral of affected side(s).

Age 40+ - Use TRAUMACAD template on AP and lateral views if available.

< Age 18 - AP on the table, Lateral and Sunrise. *No sunrise on patients under the age of 14.*

DISTANCE: 40” (48” for both standing knees on the same image).

BUCKY: YES for AP, PA and Lateral. NO for X-table and Sunrise.

FOCAL SPOT: Large

IMAGING PLATE: Standing AP/PA - 14x17 CR cassettes or DR detector.

Supine AP, Lateral and Sunrise - 10x12 CR cassettes or DR detector.

CENTRAL RAY: Perpendicular to 1” inferior to the apex of the patella.

HELPFUL POSITIONING:

1. All standing knees should be done with both shoes off.
2. **Lateral:** Angle tube 5° cephalic with knee flexed 25-30°. X-table images should be rotated to look as if they were done on table.
3. **Sunrise:** Patient is supine with affected knee supported by sunrise board. Patient's knees are flexed 45°. Place image receptor crosswise in holder so it rests on patient's tibia. Angle tube 60°. Place marker on lateral side of knee.
4. **PA Flexion:** Done standing bilaterally w/ knees flexed 45°. Angle tube caudally 10°.

SEE ALSO/OTHER VIEWS

1. **Tibial Plateau:** AP knee with a 10-15° caudal tube angle. Larger body habitus will require less angle or no angle.

[Go to “Knee- Tunnel \(Camp Coventry\)”](#)[Go to “AP Stress Knee”](#)[Go to “Knee- Tunnel \(Holmblad\)”](#)[Go to “Telos Knee”](#)

KNEE-TUNNEL (CAMP COVENTRY)

ROUTINE: Camp Coventry

DISTANCE: 40"

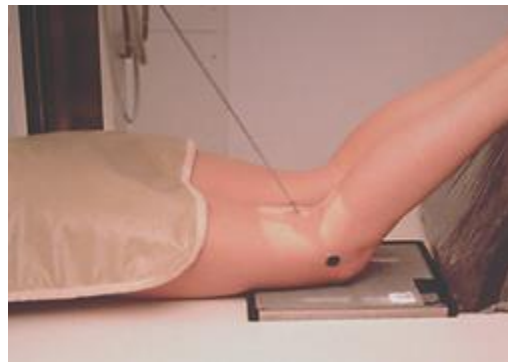
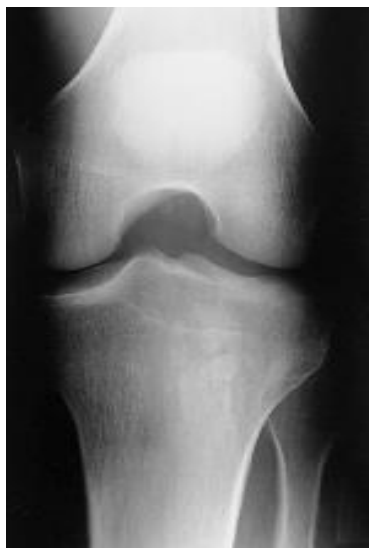BUCKY: Yes

FOCAL SPOT: Small

IMAGING PLATE: 10x12 CR cassette or DR detector

CENTRAL RAY: 40° caudal angle entering the popliteal region and exiting $\frac{1}{2}$ " inferior to the patellar apex.

HELPFUL POSITIONING: Patient is prone with affected knee flexed 40° with support under foot.



KNEE-TUNNEL (HOLMBLAD)

ROUTINE: Holmblad

DISTANCE: 40"

BUCKY: Yes

FOCAL SPOT: Small

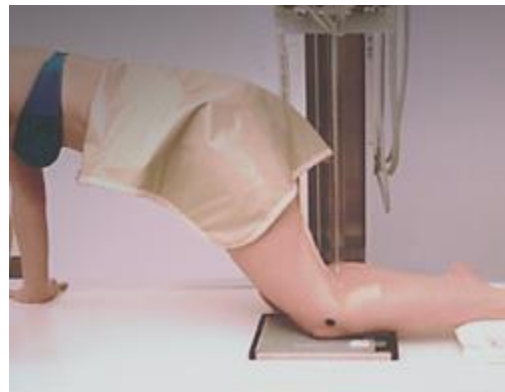
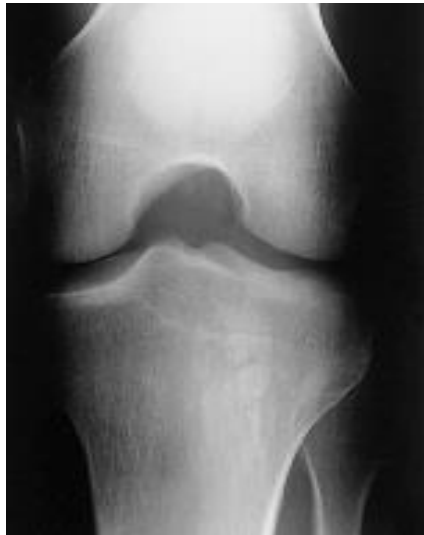IMAGING PLATE: 10x12 CR cassette or DR detector

CENTRAL RAY: Perpendicular to the image receptor entering the popliteal region and exiting $\frac{1}{2}$ " inferior to the patellar apex.

HELPFUL POSITIONING:

1. Patient is kneeling on the table. Patient leans forward so that the affected knee is flexed 70° to the tabletop.
2. If patient cannot kneel take a *Camp Coventry* view instead.

[Go to "Knee- Tunnel \(Camp Coventry\)"](#)



AP STRESS KNEE

(Commonly Ordered by Dr. Mitchell)

DISTANCE: 40"


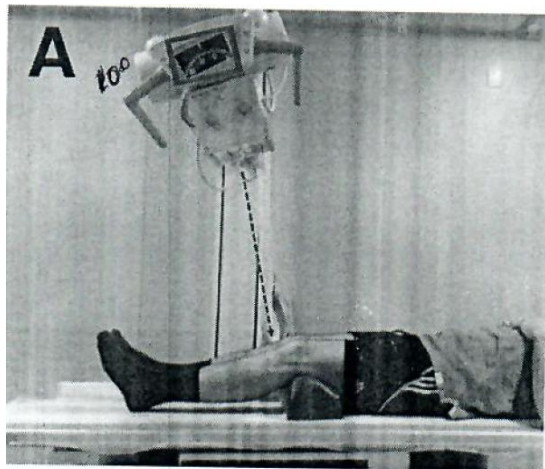
BUCKY: Yes

FOCAL SPOT: Small

IMAGING PLATE: 10x12 CR cassette or DR detector

CENTRAL RAY: 10-degree cephalic angle entering just below the apex of the patella.

POSITIONING: With patient laying on table, place knee in an AP position. Position a 45-degree sponge under their knee. *Dr. Mitchell does the stressing- have lead apron and gloves ready for him.*



TELOS KNEE

DISTANCE: 40"

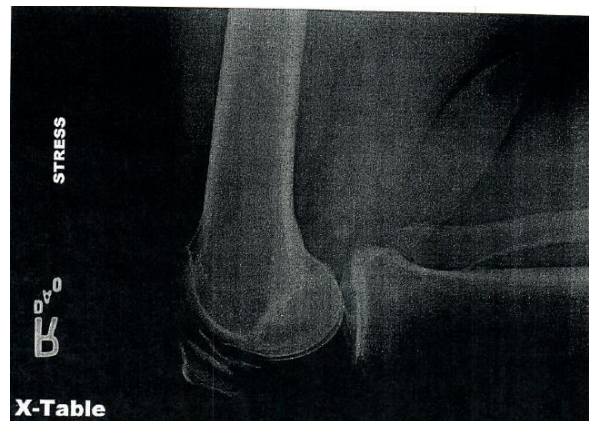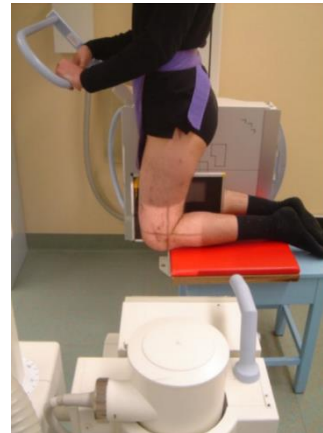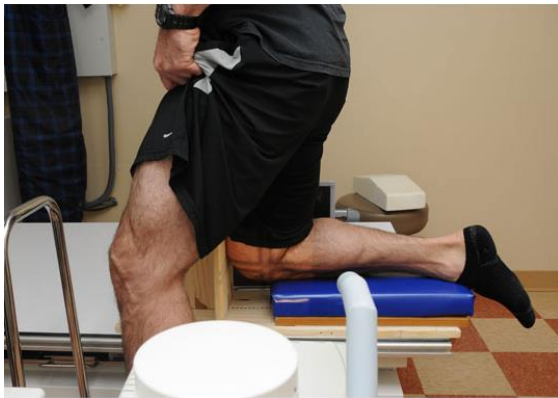BUCKY: Yes

FOCAL SPOT: Small

IMAGING PLATE: 10x12 CR cassette or DR detector

CENTRAL RAY: Perpendicular to the image receptor entering at the posterior portion of the femoral condyles.

POSITIONING: Have patient kneeling in a lateral position on a wooden block. The block should be back at bit at the level of the tibial plateau. Patient's knee should be at a 90-degree bend. Tube will be in a x-table lateral position relative to the knee and image receptor. Can be done with patient kneeling on table or the large wooden box (whatever is safest for the patient). Use a grid and a technique that is suitable for a lateral knee view for the patient body habitus.



Updated 4/13/23 sla

IMG1195L LEFT XR TIBIA/FIBULA 2 VIEWS
IMG1195R RIGHT XR TIBIA/FIBULA 2 VIEWS

TIBIA/FIBULA

ROUTINE: AP & Lateral diagonal on the image receptor with knee in the upper left corner and the ankle in the lower right corner to include both the knee and the ankle joints.

DISTANCE: 44"

BUCKY: NO

FOCAL SPOT: Large

IMAGING PLATE: 14x17 CR cassettes or DR detector

STANDING TIBIA/FIBULA

- To be done on small scoli film – no grid
- Standing on high box
- Knee must be included
- Central ray focused on or as close to ankle joint as possible

IMG1136L LEFT XR ANKLE 3+ VIEWS
IMG1136R RIGHT XR ANKLE 3+ VIEWS

ANKLE

ROUTINE: AP, Lateral & Mortise.

PAIN – NO INJURY, AGE 10+: Do weightbearing.

DISTANCE: 40”

BUCKY: NO

FOCAL SPOT: Small

IMAGING PLATE: 10x12 CR cassette or DR detector.

CENTRAL RAY: Perpendicular to the ankle joint.

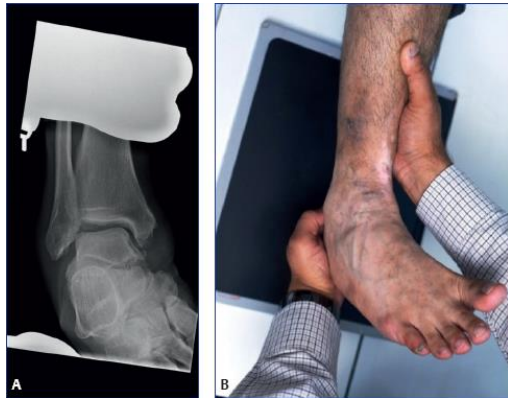ADDITIONAL COMMENTS:

1. Stress views are only taken under direction of ordering Doctor. **The Tech is NOT to apply stress!**
2. On new injuries, be sure to include the base of the 5th metatarsal on the Lateral view.
3. Specialty podiatry views- see next three pages.

ANKLE - SPECIALTY VIEWS

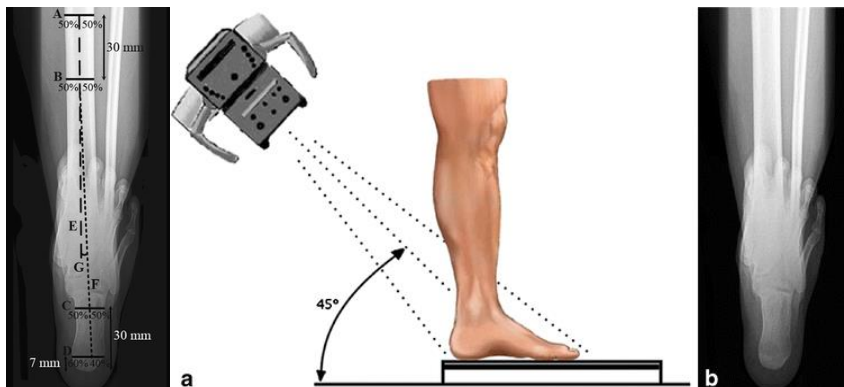
Have lead apron, thyroid shield, and lead gloves ready for the doctor if they are holding

INVERSION STRESS VIEW-NWB maximum inversion stress of affected ankle. Use 14x17 cassette or DR detector with the collimation open to include tib-fib. Ankle in AP position, with stressing as shown below. Technologist is NOT to do stressing - ordering provider does stressing!



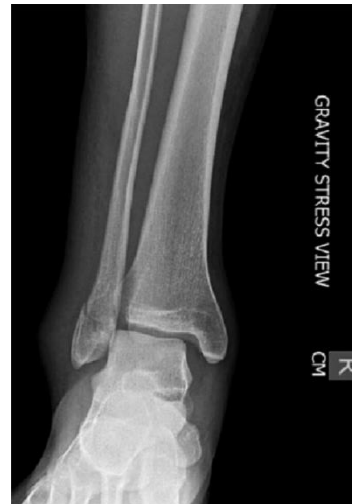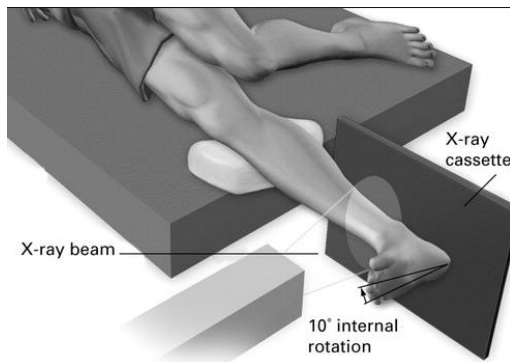
ANTERIOR DRAWER VIEW-NWB cross table view of ankle. Foot in AP position on top of a book. Press down on knee, center on ankle joint. Use 14x17 cassette or open the collimation if using a DR detector.

LONG-LEG AXIAL VIEW-Patient is standing on plexiglass (use the foot board). Tube angle 45 degrees toward the image receptor. Keep the collimator open top to bottom similar to the Hindfoot Alignment View. Place a lead strip 3mm x 2mm x 6cm behind the patient's affected heel.

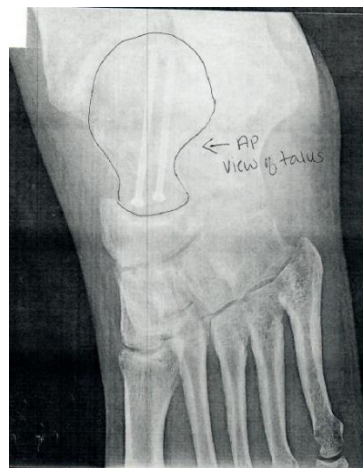
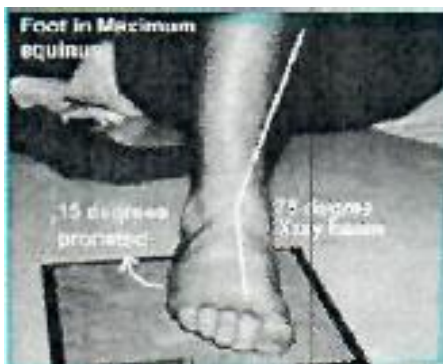

ANKLE- SPECIALTY VIEWS

GRAVITY STRESS VIEW (commonly ordered by Dr. Carrington)- Have patient lay on table on affected side with lower leg hanging off end of table to allow gravity to stress the ankle. Place a sponge between the table edge and leg for comfort and adjust the patient so the leg internally rotates 10 degrees as shown. Use grid holder to secure detector behind ankle. X-ray beam is horizontal, centered at ankle joint. (Similar to a cross-table mortise view.)



CANALE VIEW- patient will place their foot in an AP position on the board. Then have the patient internally rotate the foot 15-degrees (less than a typical oblique foot). Use a 15-degree from vertical (75-degree from horizontal) tube angle centering at toward the talus. This gives a great AP view of the Talus.



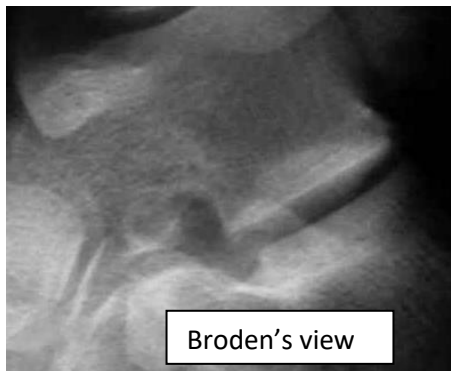
PODIATRIC SPECIALTY VIEWS

HINDFOOT ALIGNMENT-patient stands on plexiglass platform specially made for the hindfoot alignment view. The image receptor is placed in the holder, have the patient touch great toe to middle of film. Place a lead strip 3mm x 2mm x 6cm behind the patient's affected heel. The tube is at an angle of 20° off of horizontal (perpendicular to the image receptor).

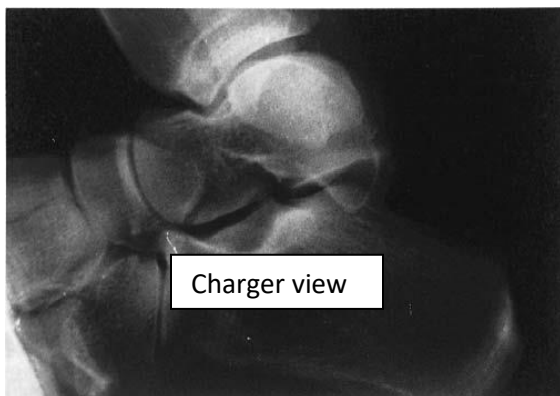
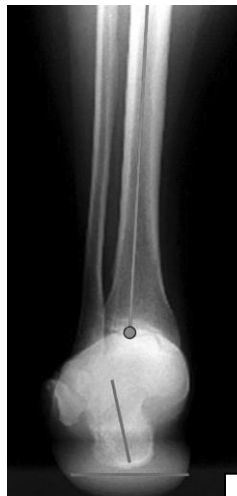CHARGER VIEW OF LATERAL ANKLE-weight bearing ankle done in dorsiflexion. The knee on the affected side is flexed to place stress on the ankle, bring the opposite leg forward for balance. The affected foot is kept flat.

SUNRISE VIEW OF THE HEEL-position similar to that of an axial heel with an angle of 20° caudad off of vertical. This view is done to visualize the posterior rim of the heel.

BRODEN'S VIEW OF THE ANKLE/HEEL-patient is laying on table with foot internally rotated 40°. Start with a 30° cephalic tube angle entering medially to the distal fibula. You may have to do several exposures, ranging between 10 and 40 degrees.



HARRIS/BEATH VIEWS (COALITION VIEWS): Position as you would a routine axial. Angle tube 30°, 35°, & 45° as central ray enters the plantar surface.



IMG1204L LEFT XR HEEL 1-2 VIEWS
IMG1204R RIGHT XR HEEL 1-2 VIEWS

OS CALCIS (HEEL)

ROUTINE: Axial & Lateral.

DISTANCE: 40"

BUCKY: NO

FOCAL SPOT: Small

IMAGING PLATE: 8x10 CR Cassette or DR detector

CENTRAL RAY:

1. **Axial:** 35-40° cephalic angle entering the plantar surface 3" superior to the base of the heel.
2. **Lateral:** CR perpendicular to image receptor at about 1 inch inferior to the medial malleolus.

HELPFUL POSITIONING:

1. Tube angled 35-40° according to the joint space.
2. **WEIGHTBEARING AXIAL:** Angle tube 40° caudal toward the posterior aspect of heel while patient is standing on plexiglass weight bearing apparatus with image receptor under the plexiglass.

ADDITIONAL COMMENTS:

Harris/Beath Views (Coalition views), Sunrise view of the heel and Broden's Views

[Go to "Podiatric Specialty Views" Page](#)

IMG1138L LEFT XR FOOT 3+ VIEWS
IMG1138R RIGHT XR FOOT 3+VIEWS

FOOT

ROUTINE: AP, Oblique & Lateral
PAIN – NO INJURY, AGE 10+: Do weightbearing.

DISTANCE: 40”

BUCKY: No

FOCAL SPOT: Small

IMAGING PLATE: 10x12 CR cassette or DR detector.

CENTRAL RAY:

1. **AP:** 10° angle toward the heel centered at the base of the 3rd metatarsal.
2. **Oblique:** 45° lateromedial tube angle centered 1” medial to the base of the 5th metatarsal.
If done non-weightbearing, oblique the foot medially 45° instead of angling tube.
3. **Lateral:** Perpendicular to the base of the 5th metatarsal.

ADDITIONAL COMMENTS:

1. Patient should not stand directly on image receptor. If your clinic does not have a weightbearing box, do non-weightbearing views.
2. Podiatry providers may occasionally order lateral obliques in addition to, or instead of, medial obliques.

SEE ALSO/OTHER VIEWS

1. **Raised Hallux:** Weightbearing Lateral foot with a roll of tape placed under the toe to raise it higher than the others.
2. **Weightbearing Sesamoids:** Have patient stand on weightbearing box and bend foot forward as far as possible, flexing toes to get heel away from the sesamoids. Tube angle will depend on the amount of foot flexion.

FOOT-CLUB FOOT

ROUTINES: AP & Lateral Simulated Weight Bearing & a Lateral with the foot in dorsiflexion.

DISTANCE: 40"

BUCKY: No

FOCAL SPOT: Small

IMAGING PLATE: 8x10 or 10x12 CR cassette or DR detector

CENTRAL RAY: Same as foot.

HELPFUL POSITIONING:

1. *AP simulated weight bearing:*
 - a. Angle 30° cephalic.
 - b. Make sure tibia is lined up with calcaneus.
 - c. Apply pressure down on bent knees.
2. *Lateral simulated weight bearing:*
 - a. Heel must be flat on plexiglass.
 - b. Apply pressure to entire base of foot.
3. *Lateral with foot in dorsiflexion.*
 - a. Use plexiglass to push up on entire base of foot.
 - b. Flex foot up toward head.

ADDITIONAL COMMENTS:

Doctor will position.

SEE ALSO/OTHER VIEWS:

1. *Plantar flexion*-force foot down.
2. *Dorsal flexion*-force foot up.

IMG1197L LEFT XR TOES 2+ VIEWS
IMG1197R RIGHT XR TOES 2+ VIEWS

TOES

ROUTINE: AP, Oblique, & Lateral Toe to include entire metatarsal.

DISTANCE: 40"

BUCKY: NO

FOCAL SPOT: Small

IMAGING PLATE: 8x10 CR cassette or DR detector.

CENTRAL RAY: Perpendicular to MP joint.

FOOT-SESAMOIDS

ROUTINE: Axial of forefoot.

DISTANCE: 40"

BUCKY: No

FOCAL SPOT: Small

IMAGING PLATE: 8x10 CR cassette or 16x16 DR detector.

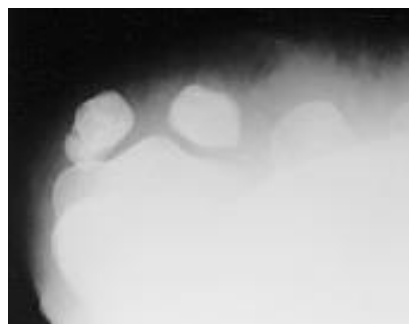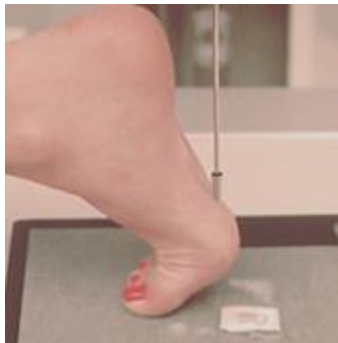CENTRAL RAY: Perpendicular to the image receptor passing through the plantar surface of the 1st MPJ.

HELPFUL POSITIONING:

1. Patient is prone with the toes dorsiflexed on the affected foot.
2. Usually easy when patient is bending forward on one knee.

ADDITIONAL COMMENTS:

1. **Supine view:** remember to pull toes forward toward the patient's body.
2. Can also be done weight-bearing, using weight bearing foot box.



PEDIATRIC TRAUMA SURVEY

ROUTINE: See views below.

DISTANCE: 40"

BUCKY: NO

FOCAL SPOT: Small

IMAGING PLATE: Appropriately sized CR cassettes or DR detector.

CENTRAL RAY: Perpendicular to the image receptor centered on appropriate part.

ADDITIONAL COMMENTS:

1. For small children, an entire extremity may be done on one image.
2. Very important to get marker on image and visualized on appropriate side.

VIEWS TAKEN:

- AP and Lateral Skull
- PA/AP Chest
- RPO Chest
- LPO Chest
- KUB
- Lateral Cervical Spine
- Lateral Thoracolumbar Spine
- PA Right and Left Hands (may be done on one image)
- AP Right and Left Feet (may be done on one image)
- AP and Lateral Right and Left Humerus
- AP and Lateral Right and Left Forearms
- AP and Lateral Right and Left Femurs
- AP and Lateral Right and Left Tibia/Fibulas

If the patient comes from the floor for a Pediatric Trauma Survey – they will most likely come with an electronic monitoring device in place.

Our protocol will be to call the floor and have them remove the bracelet, so it will not interfere with the images, and this also means that staff from the floor will need to accompany the patient for safety reasons.

BONE SURVEY COMPLETE

(ORDERED FOR METASTASIS)

ROUTINE: See views below

DISTANCE: 40" except for Lateral C-Spine & Chest done @ 72"

BUCKY: YES

FOCAL SPOT: Large

IMAGING PLATE: Appropriately sized CR cassettes or DR detector

CENTRAL RAY: Perpendicular to the image receptor centered on appropriate part.

ADDITIONAL COMMENTS:

1. Images should be dark enough to visualize mets if present. If images are too light, mets will not be seen even if present.
2. It is very important to consistently take LEFT laterals of Skull and Spines since comparisons are made periodically.

VIEWS TAKEN:

- Left Lateral Skull
- Left Lateral Cervical Spine
- AP and Lateral Lumbar Spine
- AP and Lateral Thoracic Spine
- AP Right and Left Humerus
- AP Right and Left Femurs
- AP Pelvis
- PA Chest
- RAO Chest
- LAO Chest

GENETIC BONE SURVEY

(ORDERED FOR BONE DYSPLASIA)

ROUTINE: See views below.

DISTANCE: 40" or 44" except for Lateral C-Spine done @ 72"

BUCKY: YES

FOCAL SPOT: Large

IMAGING PLATE: Use appropriate size cassettes or DR detector.

CENTRAL RAY: Perpendicular to the image receptor centered on appropriate part.

HELPFUL POSITIONING:

1. Individual images taken of each part.
2. For small children, an entire extremity may be done on one image.

ADDITIONAL COMMENTS:

Example: Done for Osteogenesis Imperfecta.

VIEWS TAKEN:

- AP/PA and Left Lateral Skull
- AP and Lateral Cervical Spine
- AP and Lateral Thoracic Spine
- AP and Lateral Lumbar Spine
- AP of **Both** arms and legs
 - Entire Humerus
 - Entire Forearm
 - Entire Femur
 - Entire Tibia/Fibula
- AP of Both hands and feet-*run under arthritic hands/feet on CR menu.*
- AP Chest
- AP Pelvis

***The ordering physician may request additional images.

LONG BONE SURVEY

ROUTINE: See views below.

DISTANCE: 40"

BUCKY: YES for femurs, NO for all others

FOCAL SPOT: Large

IMAGING PLATE: 14x17 CR cassettes or DR detector

CENTRAL RAY: Perpendicular to the image receptor centered on appropriate part.

HELPFUL POSITIONING:

1. Individual images taken of each part.
2. For small children, an entire extremity may be done on one image.

VIEWS TAKEN:

- AP view of Right and Left Tibia
- AP view of Right and Left Femur
- AP view of Right and Left Forearm
- AP view of Right and Left Humerus

SIALOGRAM

(PAROTID & SUBMAXILLARY)

ROUTINE: Parotid: Lateral Mandible, Oblique Mandible, Straight AP, SMV

Submaxillary: SMV, Lateral and Oblique Mandible & Straight AP.

DISTANCE: 40 inches

BUCKY: YES

FOCAL SPOT: Small

IMAGING PLATE: DR-16x16 Detector

ADDITIONAL COMMENTS:

Ask Radiologist which Scout images he/she wants taken.
Scout images are routinely taken and shown to a radiologist.

SUPPLIES NEEDED:

1. Sialogram tray (Central Supply)
2. Opti-visor (Cath Lab)
3. Set of dialators
4. Xylocaine (Spray viscous and ampules)
5. Pantopaque-6 cc's ampules
6. Lemon Juice packets (cafeteria)
7. Gloves
8. Needle-18 guage x 1 1/2 Green
9. Spot Light

XR POSSIBLE RETAINED SURGICAL ITEM (Missing Item in OR)

When surgery calls for an x-ray for a missing item, ask to see what item is missing. You will then x-ray the entire area of the body that the surgeon worked on, **plus take an additional x-ray of whatever they are missing.** So, if they are missing a needle or a sponge, ask for the same needle (it doesn't have to be opened) or a sponge (one dry and one wet). Note in comments: specific type of item missing and if needle – list the size. (EX: 5mm, 13mm, etc.)

Put all information in the comment section, including call back number of the OR suite for the radiologist to notify the surgeon promptly of the results. Mark as Stat & Stat Read before ending in Epic. **On off hours** refer to the department website to find out who the radiologist on call is.

If it is after an emergent case (rupture AAA or C-section), it is to make sure nothing was left behind. This is done since it is emergent, and they do not take time to count instruments before the case. Ask the surgeon if everything is off from the patient/field. This is the only way to make sure that no items are still present. If counts are not off, or they are unsure what item is missing, take an image of the general items used during the case – sharps, sponges, etc. as possible & as above list the sizes of needles.

Note :

There are reference images in PACS. Under Gundersen Health – Bottom of list – Retained Surgical Item folder if needed.

URETHROGRAM PROCEDURE

Important note: The technologist *should not* be the person pushing the contrast for this exam as these exams are usually ordered due to a suspected tear/leak. The contrast should only be pushed by the ordering provider, urologist, or radiologist.

If this exam is ordered in La crosse or a facility that has a radiologist on site and the ordering provider does not want to push the contrast/perform the exam in x-ray, they can call the radiologist (or radiology PA in La Crosse) who is on for the shift to see if they will do the exam under fluoroscopy. If the radiologist decides to do this in fluoroscopy, they will call in the fluoro technologist per their call-in protocol.

If the ordering provider is ok with performing the exam in x-ray, then they can push the contrast while the technologist makes the exposure.

ROUTINE: Scout of lower KUB to demonstrate urethra and bladder.

Second image of contrast in urethra and bladder (You may have to do two or three images to see the contrast within the urethra).

A Post Void film, if requested.

DISTANCE: 40"

BUCKY: YES

FOCAL SPOT: Large

IMAGING PLATE: DR-16x16 Detector.

CENTRAL RAY: Perpendicular to the image receptor centered at urethra.

HELPFUL POSITIONING:

Place top of image receptor at umbilicus, bottom of image receptor approximately mid-thigh- include bladder on image. Oblique the patient 45 degrees for Scout and subsequent images.

ADDITIONAL COMMENTS:

1. **CONTRAST:** Cysto Conray II (kept in the large rolling cabinet in Fluoro. Key to the locked cabinet is located in the mesh basket above the computer in the Fluoro Control area.) Contrast should be poured into a sterile basin (these can be found from the ER) and drawn up into a cath tip syringe. Supplies for the exam are found in the Clean Utility Room in the hallway by Bone Density and in fluoro. TEC has sterile basins to hold the contrast.
2. **PROCEDURE:** The ordering provider or urology provider puts the catheter in while the patient is on the X-ray table, or the patient may come to X-ray with the catheter already placed. The ordering provider or urology provider pushes 15 cc's of contrast. The technologist makes the exposure(s) on command of the physician. At least one image should show the urethra filled with contrast. A Post-Void image may be taken upon request. A urinal would be handy to have in room for patient to void into.

***There is no extra charge for the Cysto Conray II, but the contrast must be ordered in Epic prior to ending the exam.

DR. JON PETERSON - PEDS ORTHO

SCOLI

Always PA (never AP)
NO breast shielding
Expose thru acetabulum
FIRST VISIT – PA & LAT *Left hand above shoulder on the PA (for bone age)
F/Us - PA only

LLD

Standing bilat hip to ankle
Does not need ruler
Standing with feet straight forward
Will often order specific mm block – under foot of short leg

PELVIS

NON weight-bearing
Frog laterals
NO SHIELDING

FOREARM

Monteggia FX Specific Protocol
Patient is casted @ 90° with hand supinated
Take one lateral – AP forearm – separate AP elbow

- Other than the above - he will specify what he wants on each order – if you have questions just ask !
- NO shielding on any images across the board

DR. DUDLEY PROTOCOLS

SHOULDER

NEW PAIN WITH OR W/O MRI: XR Shoulder (L/R) 2+ views

-AP, Grashey/AP Neer (True AP), Scapular
Y/Lateral Neer, Axillary

2 WEEK POST-OP TSA/HEMIARTHROPLASTY: XR Shoulder (L/R) 2+ views

-AP, Grashey/AP Neer(True
AP), Scapular Y/Lateral Neer

12 WEEK POST-OP TSA/HEMIARTHROPLASTY: XR Shoulder (L/R) 2+ views

-AP, Grashey/AP Neer(True
AP), Scapular Y/Lateral Neer

ELBOW

NEW PAIN: XR Elbow (L/R) 2 views

-AP and lateral

WRIST

NEW PAIN: XR wrist (L/R) 3-5 views

-AP, oblique, lateral

S/P ORIF (2-, 4-, and 6-week post-op): XR wrist (L/R) 1-2 views

-AP and lateral

HAND/FINGERS

NEW PAIN: XR Hand (L/R) 3+ views

-PA, oblique, lateral

MASS: PA/lateral wrist/hand/finger

HIP

NEW PAIN: XR pelvis and lateral hip

-AP pelvis, AP hip, lateral hip, x-table lateral

THA (4-week and annual postop): XR pelvis and lateral hip-AP pelvis, x-table lateral

HEMIARTHROPLASTY: AP pelvis and AP hip

THA TEMPLATING: Traumacad XR Pelvis 1 View

-AP pelvis

KNEE

NEW PAIN: XR Knee Bilateral (Multiple views) *Use traumacad on AP *and* Lateral*

-Bilateral (weightbearing): AP, PA flexion, merchant/sunrise

-Affected Knee: Lateral

POST-OP: Standing (not flexed views)

TKA (4-week and annual) POSTOP: XR Knee (L/R) 3 views

-Standing (not flexed): AP, lateral, merchant

TKA TEMPLATING: XR Knee (L/R) 2 Views *Use traumacad on AP *and* Lateral*

-AP and lateral

WINONA NEW PAIN W/ OR W/O MRI: Traumacad XR Knees Bilateral (multiple views)

-Bilateral (weightbearing): AP, PA flexion, sunrise

-Affected knee: lateral

FRACTURE CARE:

NEW CONSULT: repeat x-rays

FOLLOW UP- DISTAL FIBULA FX: XR Ankle (L/R) 3+ views

-AP, mortise, lateral

FOLLOW UP- WRIST: XR wrist (L/R) 1-2 views

-AP and lateral

FOLLOW UP PELVIS FX: AP, inlet, outlet

FOLLOW UP HUMERUS FX: XR shoulder (L/R) 2+ views

-AP, scapular Y/lateral neer

FOLLOW UP CLAVICLE: AP, 30-degree cephalic

FOLLOW UP PATELLA: AP, lateral, merchant/sunrise

FOLLOW UP HAND: XR Hand (L/R) 3 views-AP, oblique, lateral

FOLLOW UP TIBIAL PLATEAU: AP and lateral

SPECIAL NOTES:

- ACL reconstruction: AP and lateral at 6-week visit
- Knee pain follow up: repeat standard series at 12-month intervals.